

**HISTOPATHOLOGY REPORTING
IN CERVICAL SCREENING**

**Working Party of the Royal College of Pathologists and the
NHS Cervical Screening Programme**

NHSCSP Publication No 10

April 1999

Withdrawn

CONTENTS

	Page No
Preface	v
Acknowledgements	vii
1. Introduction	1
2. Squamous Epithelial Abnormalities	2
3. Glandular or Columnar Cell Epithelial Abnormalities	16
4. Microinvasive Carcinoma	27
5. Invasive Carcinoma	34
6. Advice on the Reporting of Biopsies	37
7. Auditing and Quality Assurance	39
8. Clinical Importance of the Pathological Diagnosis	42
Appendix 1: General Advice on the Handling of Biopsies	45
Appendix 2: Registration of Cervical Cancers	48
Appendix 3: Electronic Data Transfer of Histopathology Results	50
References	54

Withdrawn

PREFACE

Remit of the working party

The working party was set up under the auspices of the Royal College of Pathologists and the NHS Cervical Screening Programme (NHSCSP). Its remit was to establish agreed guidelines for the reporting of cervical biopsies arising as a consequence of the cervical screening programme. It was charged with the following specific tasks:

- to provide guidelines for integrating histopathology audit into the NHSCSP
- to provide guidelines for the reporting of histopathology for the NHSCSP, areas of particular importance being the reporting of mixed cervical intraepithelial neoplasms and borderline abnormalities
- to agree criteria for microinvasive squamous carcinomas to allow conservative treatment
- to consider whether criteria can be agreed for the definition of microinvasive adenocarcinoma
- to provide guidelines to ensure that histopathologists have access to the cytopathology report when reporting the histopathology
- to provide guidelines for cytology laboratories to receive the reports of intraepithelial neoplasia and carcinoma in all cases, including when the previous cytology has been negative
- to provide guidelines for classifying cervical carcinoma and pre-cancer in an appropriate manner for transfer to cancer registries and for correlation on Department of Health statistical forms (KC61)
- to provide guidelines for the handling of specimens.

Members of the working party

Professor H Fox (Chairman)

Dr C H Buckley (Secretary), Department of Reproductive Pathology, St Mary's Hospital, Manchester

Dr A I Al-Nafussi, Department of Pathology, University of Edinburgh Medical School

Dr M C Anderson, Department of Histopathology, Queens Medical Centre, Nottingham

Professor H C Kitchener, Department of Obstetrics & Gynaecology and Reproductive Health Care, St Mary's Hospital, Manchester

Professor D G Lowe, Department of Histopathology, St Bartholomew's Hospital, London

Mrs J Patnick, NHS Breast & Cervical Screening Programmes, Sheffield

Dr T P Rollason, Department of Histopathology, Birmingham Women's Hospital

Dr P A Smith, Department of Pathology, University of Liverpool

Dr S Wells, Department of Histopathology, Royal Bolton Hospital

Withdrawn

ACKNOWLEDGEMENTS

The working party would like to thank Dr Gill Lawrence for advice on registration of cervical cancers and Dr Mike Light for advice on electronic transfer of histopathology results. They are also grateful to Professor David Lowe for his editorial advice and assistance.

Withdrawn

Withdrawn

1. INTRODUCTION

1.1 Multidisciplinary working

Cervical screening is a multidisciplinary activity in which the various components of a programme must work with the same objectives, protocols and definitions in order to be effective. The philosophy of teamworking should extend throughout the programme from identification of the target population through to diagnosis and evaluation of the programme. Each component part of the screening programme must recognise the needs and limitations of other providers. Multidisciplinary audit across professional boundaries is vital to the provision and maintenance of a high-quality screening programme. This must cover not only the management of individual women, particularly those with invasive cancer, but also working practices and interdisciplinary cooperation. Audits must include the sharing of information among professionals.

1.2 Correlation between cytology and histology

A cervical biopsy is part of the screening process. It follows a referral, the need for which has been indicated by the cervical smear report. A biopsy has several functions. It confirms, alters or refutes the suggested diagnosis and, in some cases, it adequately treats the lesion. Correlation between the findings in a cervical smear and the subsequent histological specimen is an integral component of the NHS Cervical Screening Programme. It ensures that the biopsy is reported in the context of the cytological findings and acts as a means of monitoring the efficiency and accuracy of the screening process.

Information about departmental practices and individual cases must be freely shared within the screening programme. It is expected that cytology reports will be available to the colposcopist when examining the woman and also to the histopathologist when reporting biopsies. Similarly, clinical reports must be made available to the histopathologist. In this way, professionals will have access to all the information on a patient and be able to exercise their judgement (and make recommendations) most appropriately. Histological findings have important quality control and audit functions in ensuring that the cervical screening programme is correctly identifying those women who need further investigation or treatment. The importance of having available the cytological and histopathological specimens together for auditing and quality assurance of the cervical screening programme is discussed in Chapter 7.

1.3 Types of biopsy

The types of biopsy covered by this report include cervical punch biopsies, wedge biopsies, loop excisions and cone biopsies. Advice on the handling of these biopsies is given in Appendix 1. Although a hysterectomy would not normally be the chosen method of managing a woman with an abnormal cervical smear, a hysterectomy may sometimes be performed in someone with an abnormal smear in whom there are other clinical indications for a hysterectomy. Guidance on the handling of such specimens is therefore also included.

2. SQUAMOUS EPITHELIAL ABNORMALITIES

2.1 Cervical intraepithelial neoplasia (CIN)

It is recommended that cytopathologists and histopathologists in the UK should continue to use the CIN terminology for the histological description of squamous intraepithelial neoplasia. The arguments for this have been well rehearsed.¹

In summary, they are:

- cervical intraepithelial neoplasia is a descriptive term and does not involve a value judgement
- the use of three grades underlines the concept of continuity of CIN more than does a two-grade system
- the terms are easy to use and the system is well established and allows correlation with the cytological grades of dyskaryosis
- the terms allow continuity of the database and ensure that historical reviews can be undertaken.

The Bethesda system was introduced to deal with a problem which was being experienced in the United States and has no advantage for those practising pathology in Europe.² Its disadvantages are:

- it does not improve the objectivity of the report
- it creates the illusion that intraepithelial neoplasia in the cervix is a two-tier disease, whereas it is well recognised that it forms a continuum
- it calls for a value judgement based only on the morphology of the lesion
- it includes non-neoplastic lesions.¹

The CIN terminology must be used not only for the description of squamous intraepithelial neoplasia of the cervix but also for correlation of cytological and histopathological findings and for the transfer of data to cancer registries. It is important that the cancer registries use the same terminology as histopathologists for the storage of data on cervical intraepithelial neoplasia. The inclusion of CIN1 and 2 on the database would assist the complete evaluation of the effectiveness of the cervical screening programme. Further details of the requirements for transfer of data to cancer registries are given in Appendix 2.

The histological features of CIN are well documented.¹ The features that distinguish CIN from reactive and other non-neoplastic histological changes are emphasised below, as are important aspects of the reporting of CIN lesions.

The minimum histological change that justifies a diagnosis of CIN1 is the presence, throughout the full thickness of the epithelium, of some degree of nuclear abnormality (Figure 1).¹ The abnormalities are most

2.1.1 *Minimum criteria for the diagnosis of CIN1*

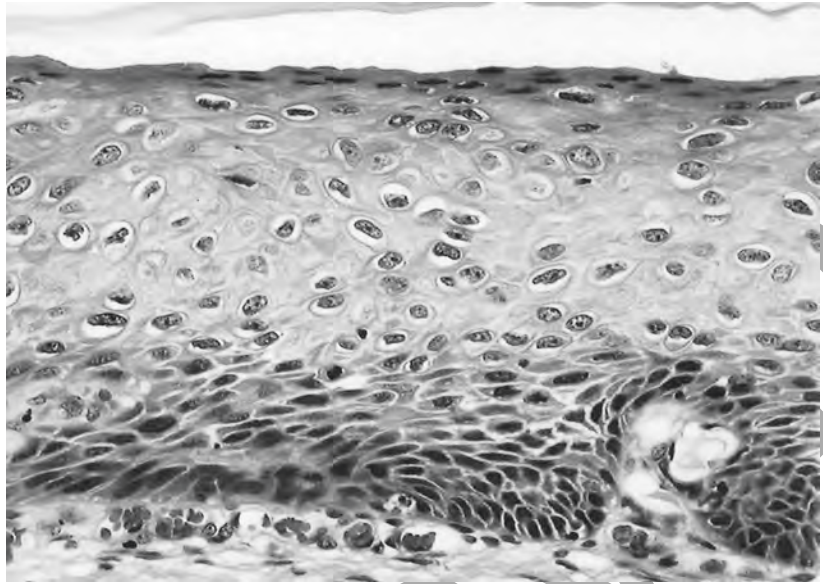


Figure 1 CIN1. The nuclear changes are mild, though some abnormality extends throughout the full thickness of the epithelium.

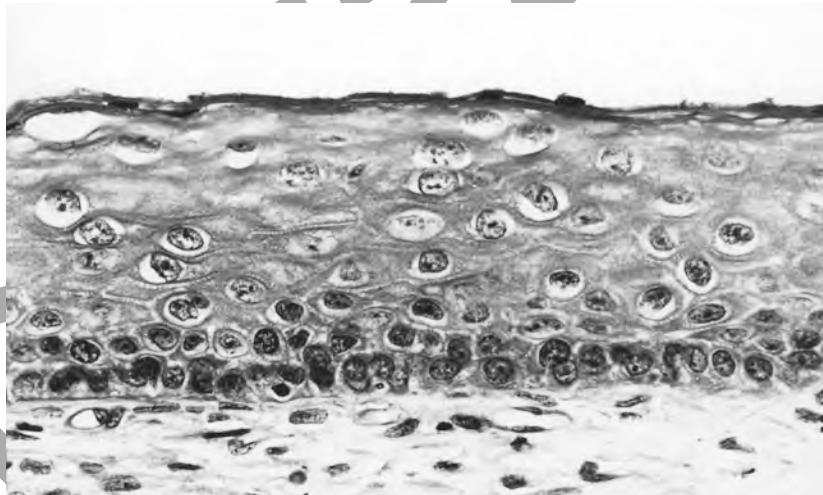


Figure 2 CIN1. The nuclear abnormalities are most apparent in the basal third of the epithelium, but a mild degree of nuclear abnormality is present throughout the full thickness of the epithelium.

apparent in the basal third of the epithelium (Figure 2). These nuclear abnormalities are as follows:

- a mild degree of nuclear pleomorphism
- an increase in nuclear–cytoplasmic ratio
- some degree of nuclear enlargement
- mild hyperchromasia with a finely stippled chromatin pattern.

The presence of normal mitotic figures is not helpful in making the diagnosis, but abnormal mitoses (Figure 3) support the diagnosis of CIN1. The abnormalities in mitotic figures are often subtle and focal, necessitating the examination of an adequate number of sections (Figure

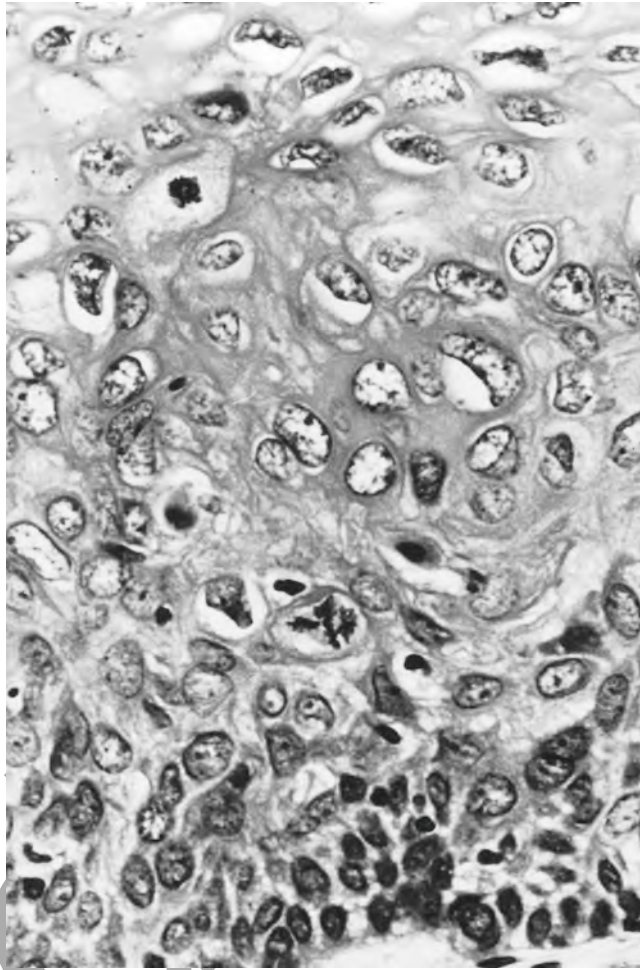


Figure 3 CIN1 with an obvious quadripolar mitotic figure.

4).^{3,4} Cytoplasmic maturation is limited to the upper two-thirds of the epithelium.

The features of CIN1 can be found in mature, immature (Figure 5), atrophic and shallow epithelium and in epithelium in which there are koilocytes or koilocyte-associated features (Figure 6) (see paragraph 2.2.1). Grading of CIN, in terms of the proportion of the epithelium occupied by undifferentiated cells, may be difficult or impossible in shallow or immature metaplastic squamous epithelium. In such cases, a diagnosis of CIN (ungraded) should be made (Figure 7).

In any example of CIN1, the expression of the different features varies, so that all those listed are not necessarily to be found in every example of CIN1. Nuclear pleomorphism and nuclear enlargement are, however, the essential features for diagnosis.

2.1.2 *Defining features of CIN2 and 3*

The diagnoses of CIN2 and 3 are more robust than that of CIN1. It is sufficient, therefore, to iterate that in CIN2 (Figure 8) the nuclear atypia again extends through the full thickness of the epithelium and is more severe than in CIN1: cytoplasmic maturation commences in the middle third of the epithelium. In CIN3 (Figure 9), the degree of nuclear atypia

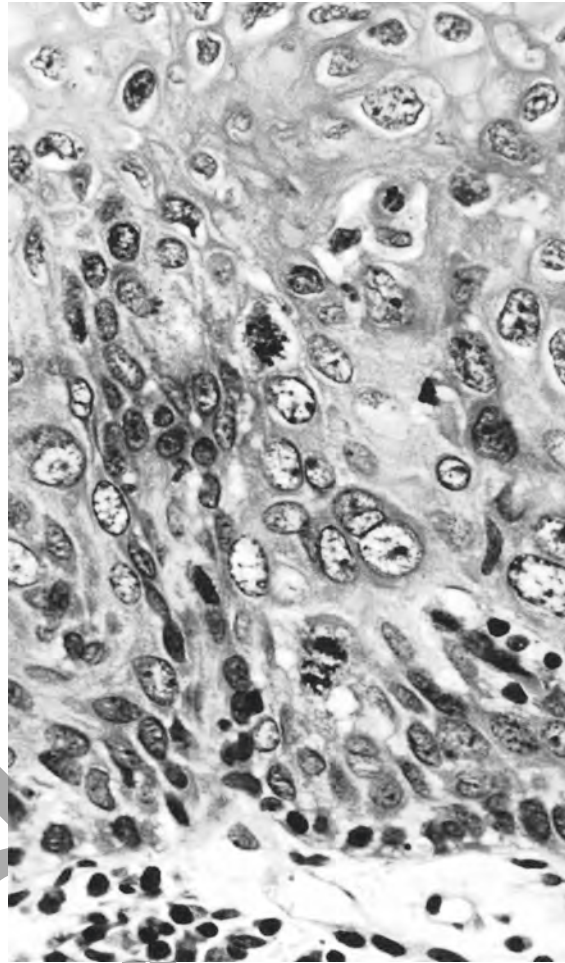


Figure 4 CIN1. Subtle abnormalities of mitotic figures (dispersed metaphase).

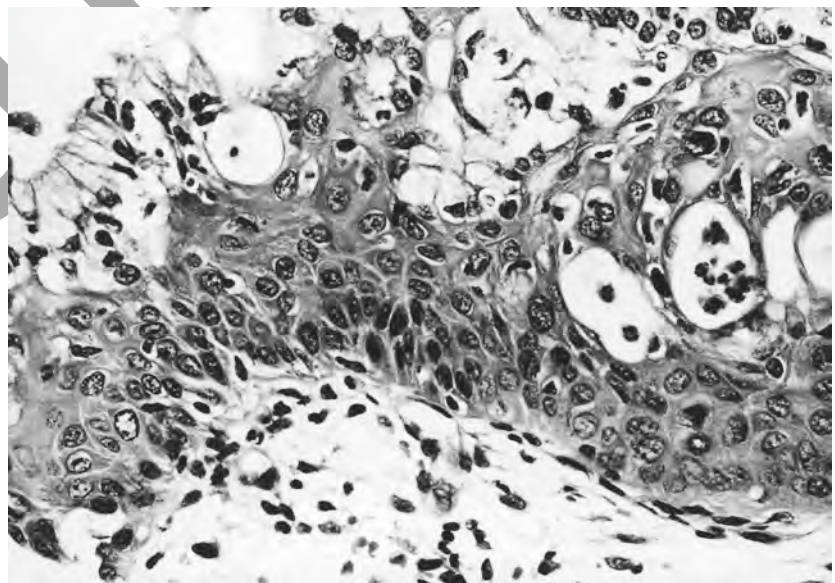


Figure 5 Squamous metaplasia with nuclear pleomorphism and hyperchromasia. A diagnosis of CIN should be made in these circumstances; this example has the features of CIN1.

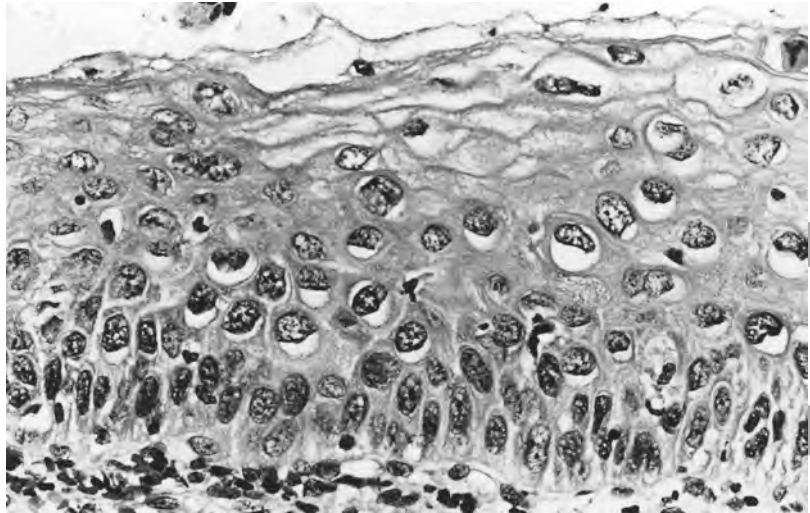


Figure 6 CIN1 with koilocytes.

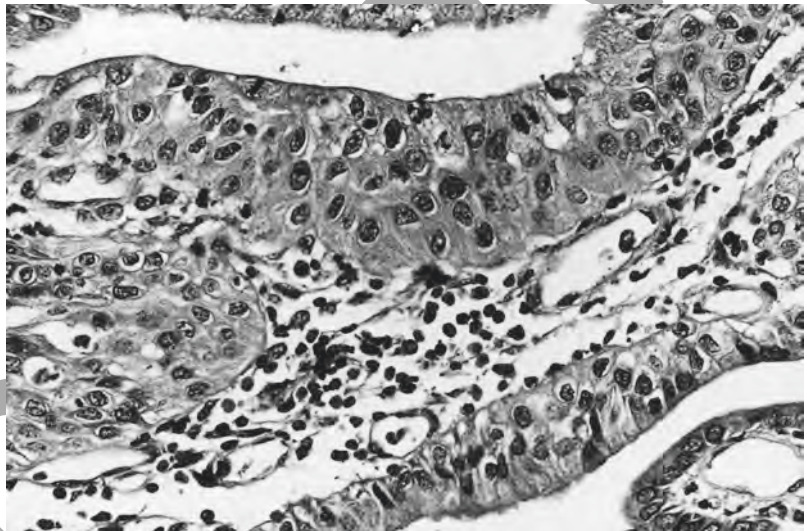


Figure 7 CIN (ungraded). The degree of nuclear pleomorphism and hyperchromasia is mild but is sufficient for a diagnosis of CIN in this shallow, rather immature epithelium; grading of the CIN is not possible.

is greater than in either of the two lower grades and is generally accompanied by a larger number of mitoses often at all levels in the tissue: no cytoplasmic maturation is present or only a little in the outer third of the epithelium.

2.1.3 Reporting of squamous intraepithelial neoplasia

1. The cervical smear findings indicate the minimum abnormality to be expected in the subsequent biopsy. The biopsy finding of CIN3 in a woman in whom a smear revealed mild dyskaryosis should not, therefore, be regarded as failure of the screening programme. It is also important to appreciate that in a small number of women an unexpected invasive lesion will be identified. This too should not necessarily be regarded as a failure of the screening system.
2. The presence of normal mitoses at a high level in a squamous epithelium is not indicative of intraepithelial neoplasia. They can be disregarded if there are no other features of CIN.

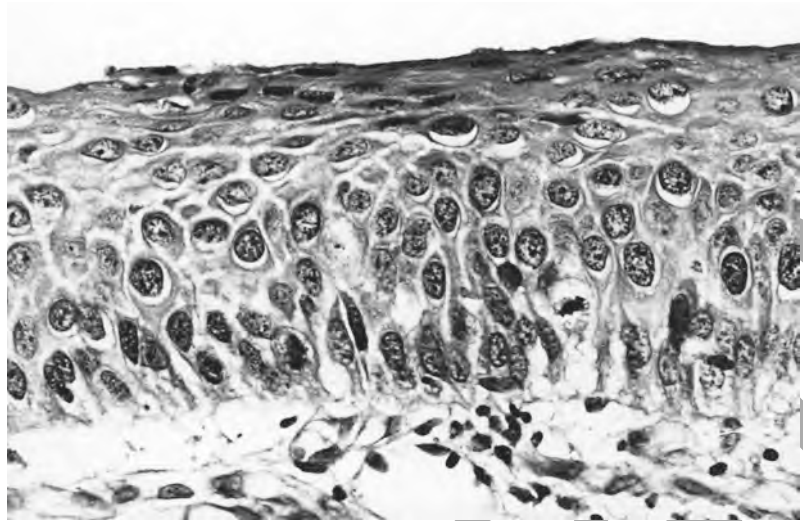


Figure 8 CIN2.

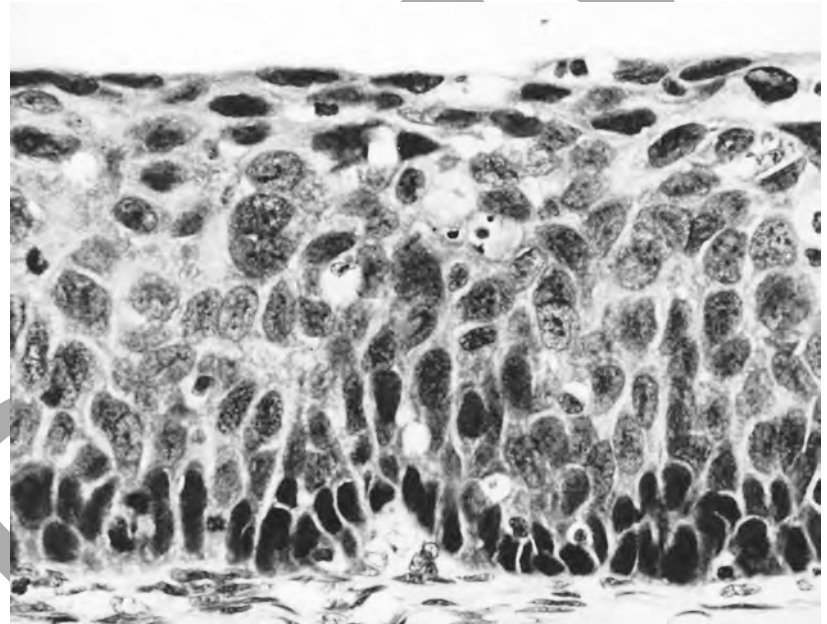


Figure 9 CIN3.

3. A diagnosis of ungraded CIN is appropriate when the epithelium is too thin to permit the use of the normal grading features of CIN (Figure 10). It is recommended that, if the pathologist is confident that CIN is present, even in a thin or inflamed epithelium, this diagnosis must be made even if the CIN has to remain ungraded (Figures 11 and 12). It is also recommended that, where possible, the report gives some indication as to whether the lesion is CIN1 to 2 or CIN2 to 3, so that management can be appropriately planned.
4. All grades of CIN present must be mentioned in the histology report.

2.2 Human papillomavirus (HPV)-associated changes

Koilocytosis has been regarded as pathognomonic of HPV infection, but there is now evidence that other viruses may cause or be associated with similar changes.⁵ Equally, HPV infection may be present in the absence of koilocytes. As a consequence, the following terminology is recommended for those lesions in which there is koilocytosis:

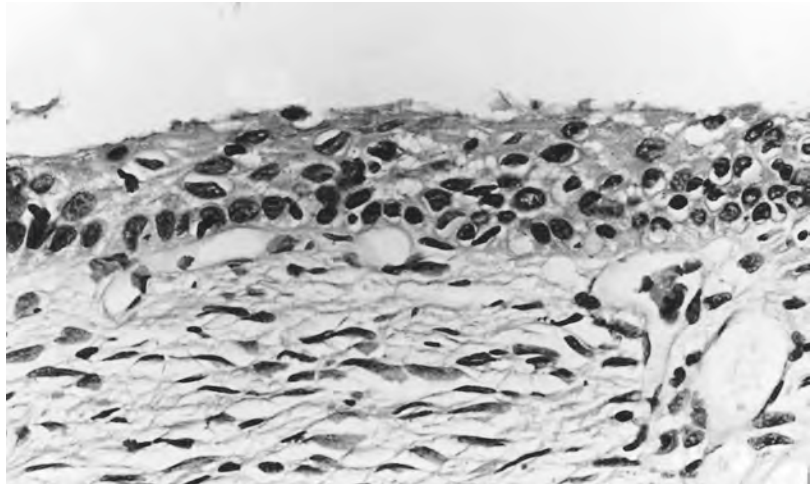


Figure 10 CIN (ungraded). There is nuclear pleomorphism and hyperchromasia throughout the full thickness of this epithelium and this warrants a diagnosis of CIN. Accurate grading is impossible in this thin epithelium, though it is probably CIN1 to 2 rather than CIN2 to 3.

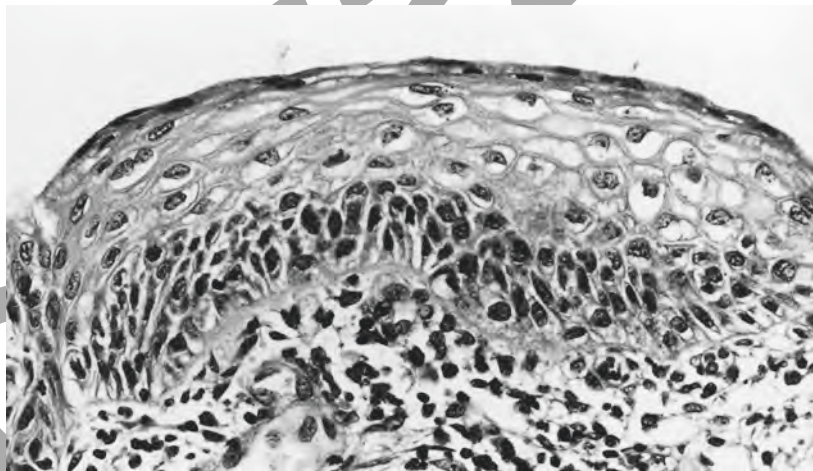


Figure 11 CIN1. Despite the inflammation in this tissue, there are undoubted features of CIN in the epithelium. Note that, since 1991, there has been a change in the classification of this abnormality.¹

- those squamous epithelial lesions in which there is koilocytosis only should be reported as ‘koilocytosis only’
- those lesions in which there is koilocytosis associated with epithelial multinucleation, individual cell keratinisation, parakeratosis, acanthosis and papillomatosis should be described as ‘koilocytosis-associated features only’ or ‘HPV-like features’
- if the lesion is papillary and clearly forms a condyloma acuminatum, this should be stated, as should the presence of a spiky, hyperkeratotic but non-papillary lesion that has a specific colposcopic appearance (Figure 13).

It is important that koilocytosis and koilocytosis-associated lesions are carefully sought and consistently reported in all cases as the cytological

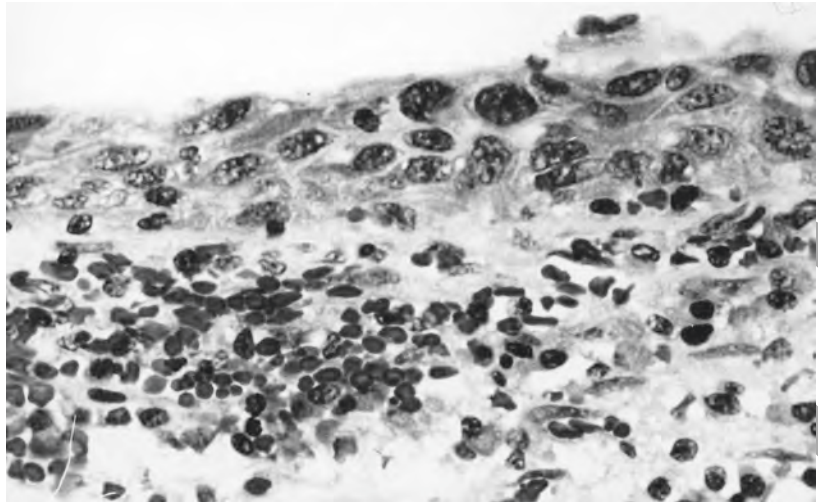


Figure 12 CIN (ungraded). The epithelium is only a few cells thick and, although the presence of nuclear abnormalities is unequivocal, confident grading is not possible. The degree of nuclear atypia, however, suggests that this is CIN2 to 3 rather than CIN1 to 2.

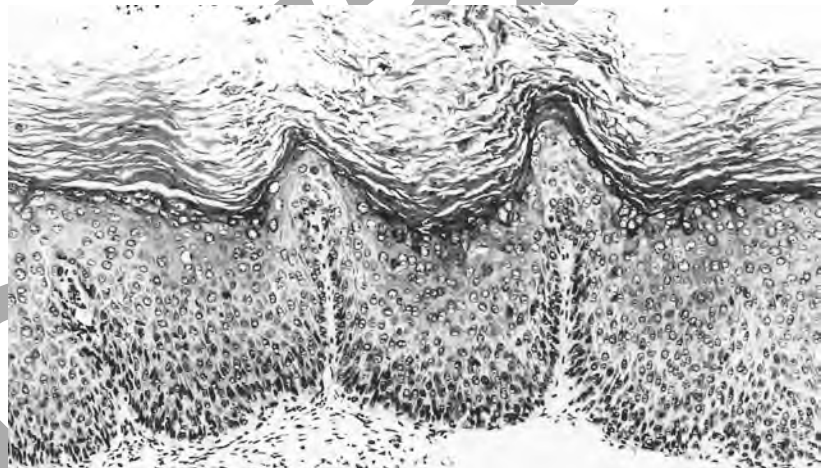


Figure 13 HPV-like changes. A spiky, hyperkeratotic, non-papillary lesion. Koilocytes are present but only anucleate squames or dyskeratotic cells may have been present in the cervical smear.

diagnosis of mild dyskaryosis may be explained by the finding of koilocytosis-associated features only.

2.2.1 Recognition of koilocytes and koilocytosis-associated changes

A cell should be described as a koilocyte (Figure 14) only when the nucleus has a wrinkled outline, is enlarged and is hyperchromatic and when there is a sharply etched perinuclear clearing of the cytoplasm. Koilocytes are rarely present in the basal layers of the epithelium, and then usually only when they are also present in the more superficial layers. Koilocytosis may be remarkably focal, and it is essential to examine sufficient sections from a block if these microscopic foci are not to be missed.

In the absence of CIN, the basal layers of an epithelium in which there are koilocytes do not show nuclear pleomorphism (Figure 15). The nuclei

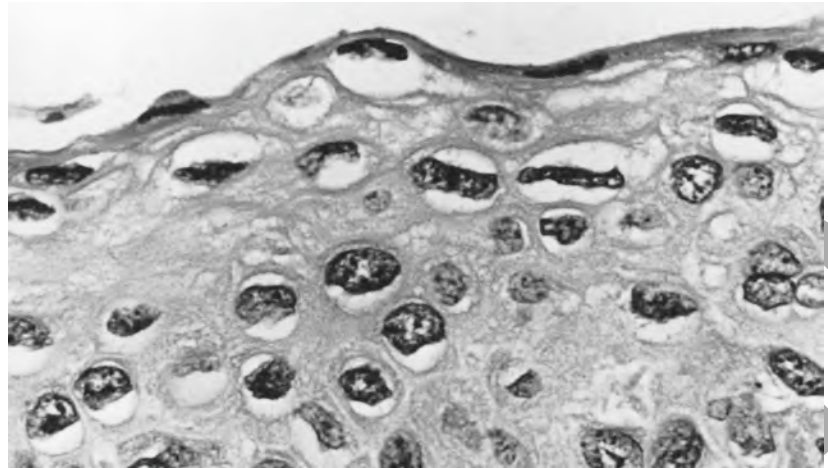


Figure 14 Koilocytes. The nuclei of affected cells are enlarged and hyperchromatic with a wrinkled outline. There is sharply etched perinuclear clearing of the cytoplasm. Note the multinucleated cell to the right.

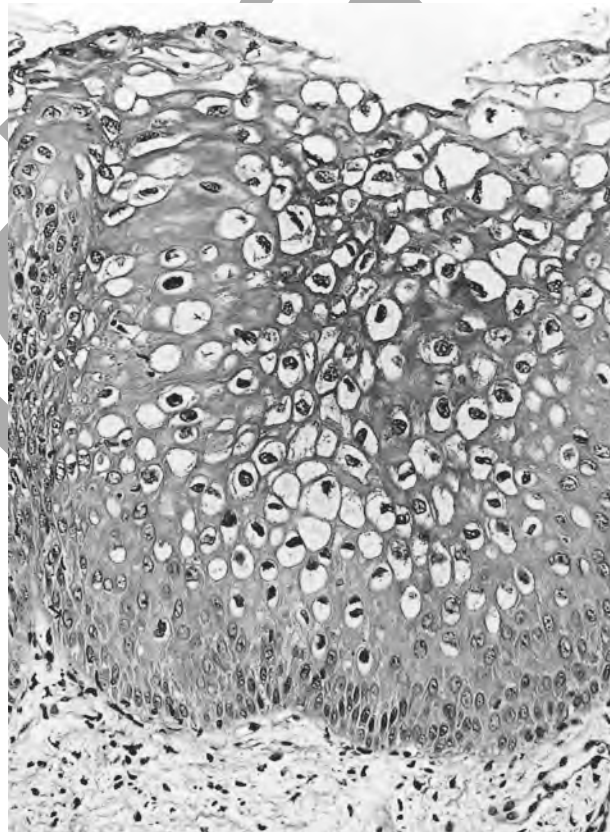


Figure 15 HPV-like changes. No basal cell hyperplasia or CIN is present.

of the cells in the basal layers may, however, be uniformly enlarged as a manifestation of basal cell hyperplasia (Figure 16). The presence of even numerous normal mitotic figures is consistent with a diagnosis of koilocytosis only.

2.2.2 Koilocytosis with CIN

When CIN and koilocytosis and koilocytosis-associated features coexist, the CIN must be graded. The citing of all grades in the report will allow

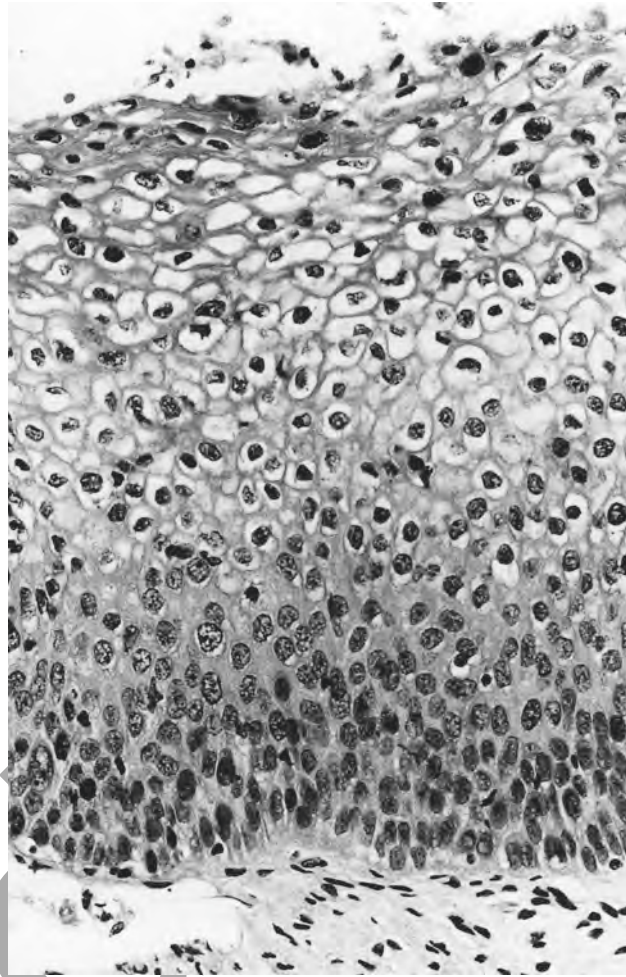


Figure 16 HPV-like changes with basal cell hyperplasia.

correlation with the cervical cytology. The koilocytosis and koilocytosis-associated changes should also be described in the report to allow accurate correlation with the cervical cytology. CIN, even in the presence of koilocytosis or koilocytosis-associated changes, is recognised by exactly the same criteria as in the absence of koilocytosis. The nuclear changes may, however, appear exaggerated and there is a tendency to attribute too high a grade of CIN, which should be resisted.

When koilocytosis or koilocytosis-associated lesions contain atypical mitoses, in the absence of other features of CIN, the lesion should be described as ‘ungraded CIN’ (Figure 17). For management purposes, this can be regarded as no more than CIN1. Other non-neoplastic lesions which may be associated with abnormal cervical cytology should also be listed in the histopathology report (see below).

2.3 Borderline lesions

Previous advice on the reporting of CIN in the presence of severe inflammation and in a thin epithelium has been amended (see paragraph 2.1.3), but there remains a need for a category to encompass those lesions in which the histopathologist is uncertain about the presence or absence of CIN1. The term ‘epithelial changes of uncertain significance’ is

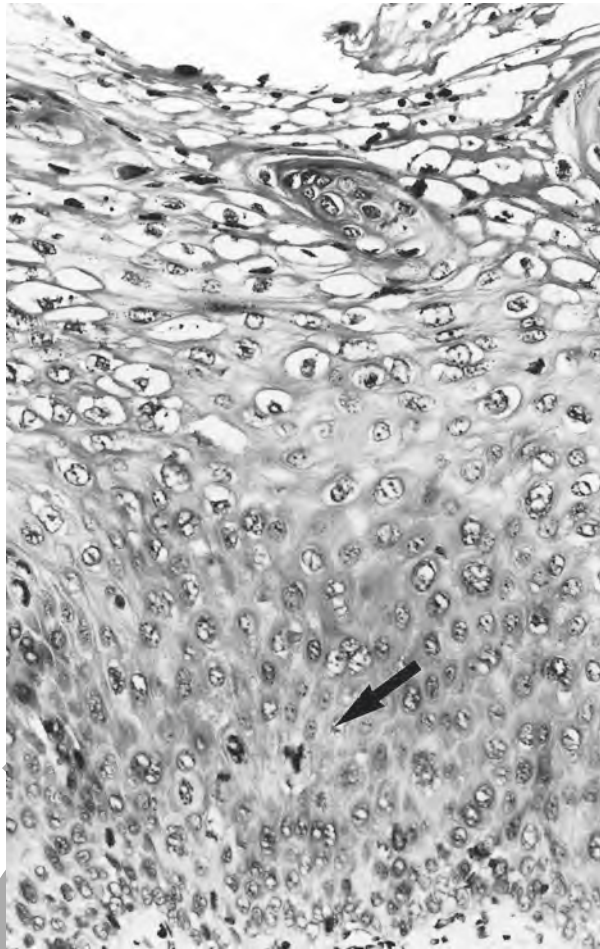

Figure 17 HPV-like changes with CIN. There is little or no nuclear pleomorphism or hyperchromasia in the basal layers of the epithelium but there is a tripolar mitosis in the parabasal layers. This warrants a diagnosis of CIN (ungraded).

recommended. The pathologist should, however, make every attempt to distinguish this lesion from CIN1.

Features that may be found in these circumstances include:

- a minor degree of nuclear pleomorphism limited to the basal layers (Figure 18) in the absence of severe inflammation
- normal mitoses
- koilocytosis or koilocytosis-associated features.

Cytological abnormalities may be seen in the presence of various non-neoplastic lesions, in addition to koilocytosis and koilocytosis-associated lesions. It is important that these are mentioned in the histological report to allow correlation between the cytological and histological findings.

Basal cell hyperplasia is characterised by the presence of regular replication of the basal layers of the epithelium associated with nuclear enlargement and a mild degree of hyperchromasia: nuclear pleomorphism is absent (Figure 16). This common finding must not be confused

2.4 Areas of diagnostic difficulty

2.4.1 Basal cell hyperplasia

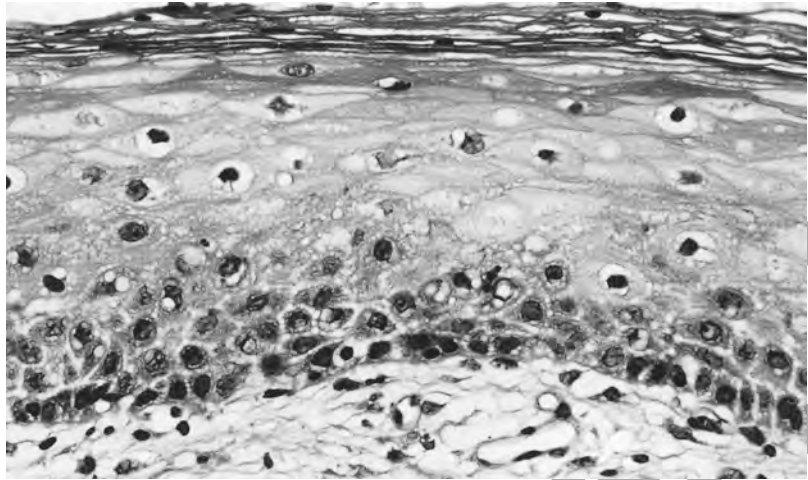


Figure 18 Epithelial changes of uncertain significance. The degree of nuclear abnormality is less than that which is required for a diagnosis of CIN. No inflammation is present.

histologically with CIN and should not alone be regarded as an explanation of a smear in which dyskaryosis was detected. If the basal cell hyperplasia is, however, associated with severe inflammation, there may have been cells in the preceding smear which were reported as having borderline nuclear changes.

2.4.2 Squamous metaplasia

Squamous metaplasia is a physiological process characterised by reserve cell hyperplasia (Figure 19), early squamous differentiation, variable cellular polarity and nuclear enlargement: nuclear pleomorphism and hyperchromasia are absent. Similar changes can be seen in an epithelium healing after treatment. There may or may not be columnar cells on the surface of the epithelium (Figure 20). If there is sufficient nuclear pleomorphism, a diagnosis of CIN should be made even if columnar

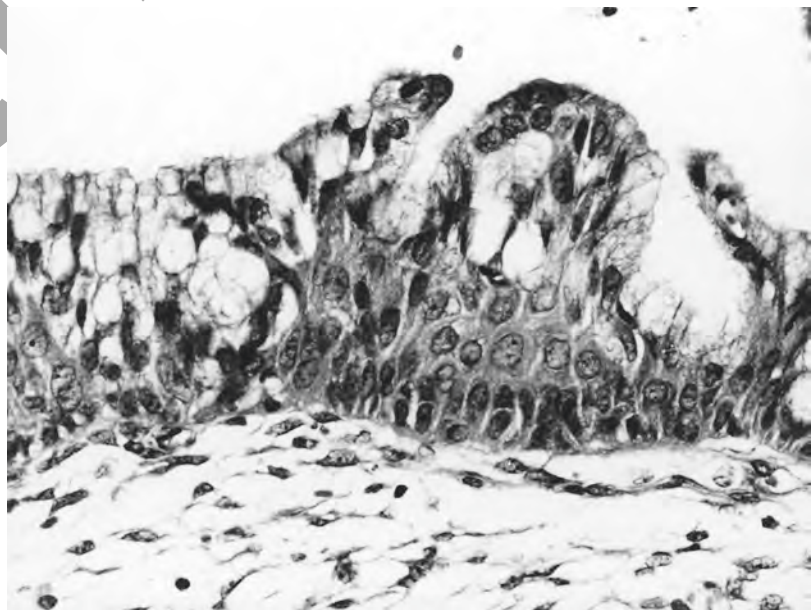


Figure 19 Reserve cell hyperplasia.

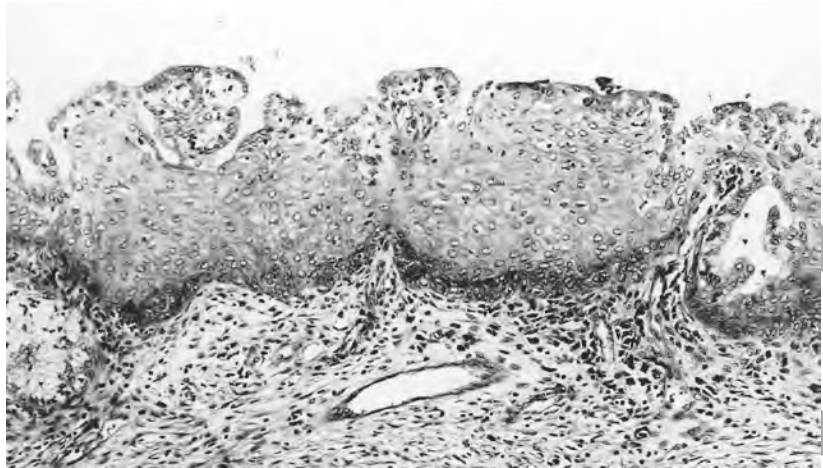


Figure 20 Immature metaplastic squamous epithelium. Although a minor degree of nuclear enlargement is present, there is no nuclear pleomorphism or hyperchromasia.

cells are present on the surface (Figure 5). Microglandular hyperplasia (see paragraph 3.2.8) may also contain areas of immature metaplastic squamous epithelium. The preceding smear may also have been reported as containing cells with nuclear changes of borderline significance, particularly when there is associated inflammation or microglandular hyperplasia.

2.4.3 Low-oestrogen states

In low-oestrogen states, for example after the menopause or in women using low-oestrogen contraceptives, the cervical squamous epithelium may be composed entirely of cells of parabasal type and is usually thin (Figure 21). A mild degree of hyperchromasia is often a feature of such an epithelium, but in the absence of pleomorphism CIN should not be diagnosed. If nuclear pleomorphism is present, a diagnosis of CIN is appropriate. Grading according to the proportion of epithelium occupied by undifferentiated cells may be difficult or impossible, and in such

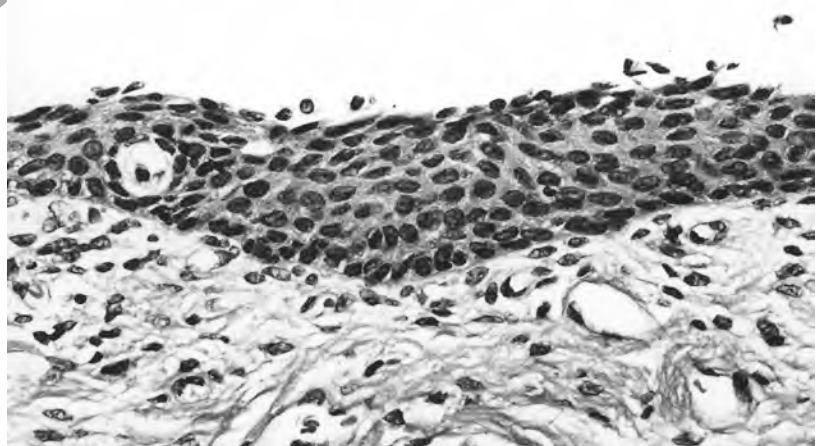


Figure 21 Atrophic squamous epithelium, composed entirely of cells of parabasal type. Although there is mild hyperchromasia, no nuclear pleomorphism is present.

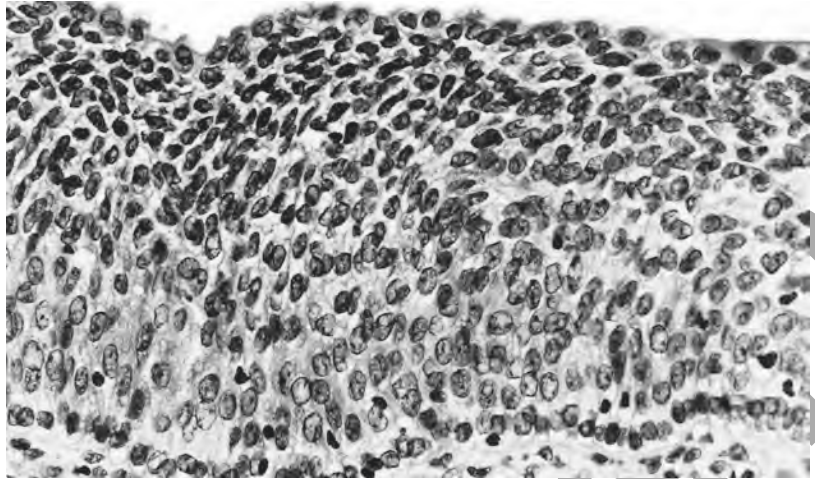


Figure 22 Transitional cell metaplasia. The epithelium is formed by a uniform population of cells with oval to round regular nuclei. There are high nucleocytoplasmic ratios but there is neither mitotic activity nor abnormal nuclear chromatin dispersion.

cases a diagnosis of CIN (ungraded) should be made. When the epithelium is severely atrophic, the cervical smear may contain individual cells or sheets of cells which are sometimes difficult to distinguish from severely dyskaryotic cells.⁶

2.4.4 *Transitional cell metaplasia*

In some individuals, the squamous epithelium of the ectocervix and the transformation zone may undergo so-called transitional cell metaplasia. Such metaplasia is often widespread and is characterised by the presence, through the full thickness of the epithelium, of a uniform population of cells with oval to round regular nuclei, which are occasionally grooved, high nuclear–cytoplasmic ratios and the lack of both mitotic activity and abnormal nuclear chromatin dispersion (Figure 22).⁷

3. GLANDULAR OR COLUMNAR CELL EPITHELIAL ABNORMALITIES

3.1 Cervical glandular intraepithelial neoplasia (CGIN)

The natural history of cervical glandular intraepithelial neoplasia is less well understood than that of squamous intraepithelial neoplasia, with which it is often associated (Figure 23). It affects the surface epithelium and the endocervical crypts and in some cases is discontinuous or multifocal.⁸ It is recognised histologically by a combination of architectural and cytological abnormalities, though a consistent feature is the presence of nuclear abnormalities. These include the following features, not all of which are required for a diagnosis:

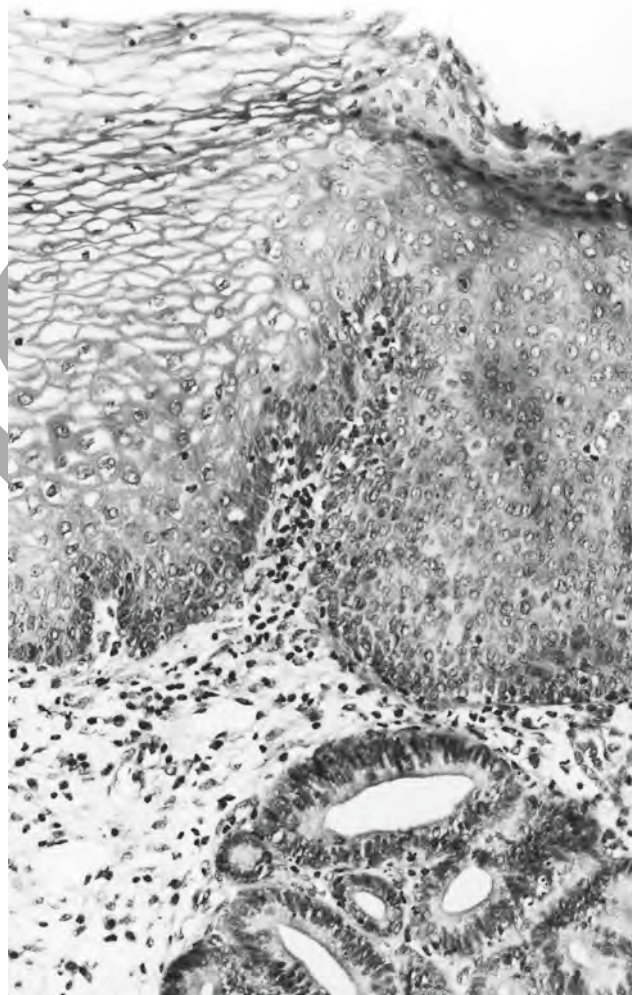


Figure 23 CIN1 and CGIN in close proximity. The squamous epithelium to the left is normal, whereas that to the right has the features of CIN, and cluster of underlying crypts are lined by an atypical columnar epithelium with the features of CGIN.

Architectural features (Figures 24–26)

- glandular crowding
- glandular branching
- glandular budding
- intraluminal papillary projections
- cribriform pattern.

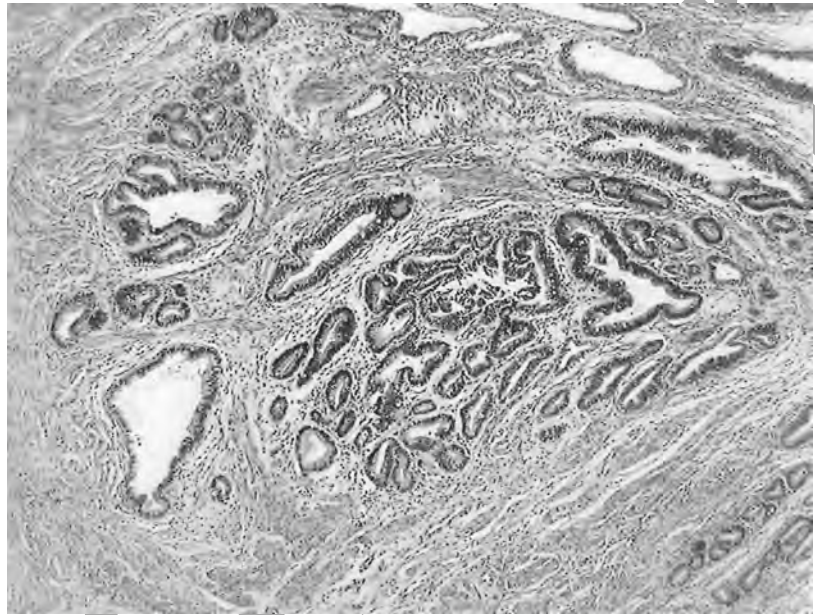


Figure 24 CGIN. A cluster of closely packed glands with branching, out-pouchings and occasional in-foldings of the epithelium.

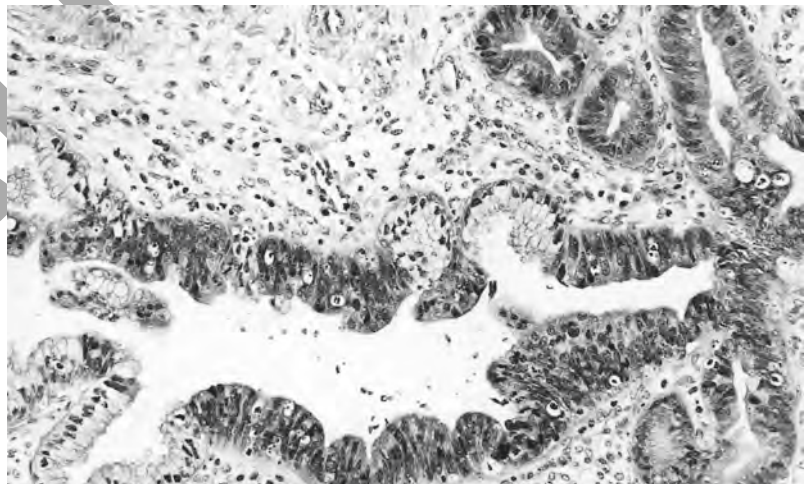


Figure 25 CGIN. Crypts lined partly by normal endocervical columnar epithelium and partly by a stratified columnar epithelium in which there is nuclear enlargement and hyperchromasia. Note the branching of the crypts to the right of the figure.

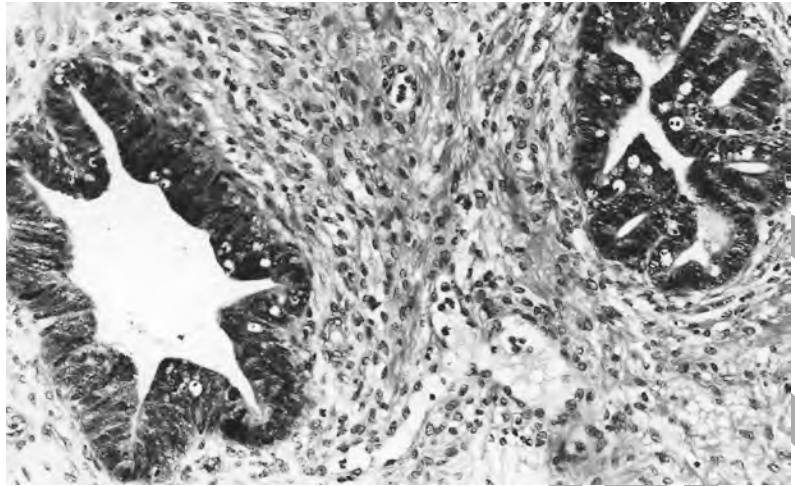


Figure 26 CGIN. There is budding from the crypt to the right, which creates a cribriform-like pattern.

Cytological features (Figures 27–30)

- abrupt junction between the normal columnar epithelium and the CGIN
- intestinal metaplasia/goblet cell formation
- loss of mucin secretion in cells of endocervical type
- cellular stratification but only when combined with nuclear changes
- nuclear enlargement
- loss of nuclear polarity
- nuclear pleomorphism
- nuclear hyperchromasia
- mitotic activity, some of which may be of abnormal forms
- the presence of prominent nucleoli
- apoptosis.

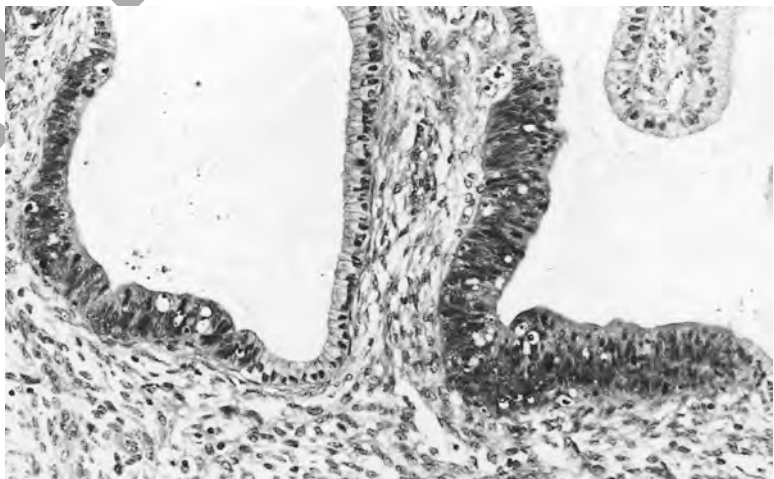


Figure 27 CGIN. There is an abrupt transition in both these crypts from normal endocervical columnar epithelium to the stratified epithelium of the CGIN in which there is a reduction in cytoplasmic mucin, nuclear enlargement and hyperchromasia.

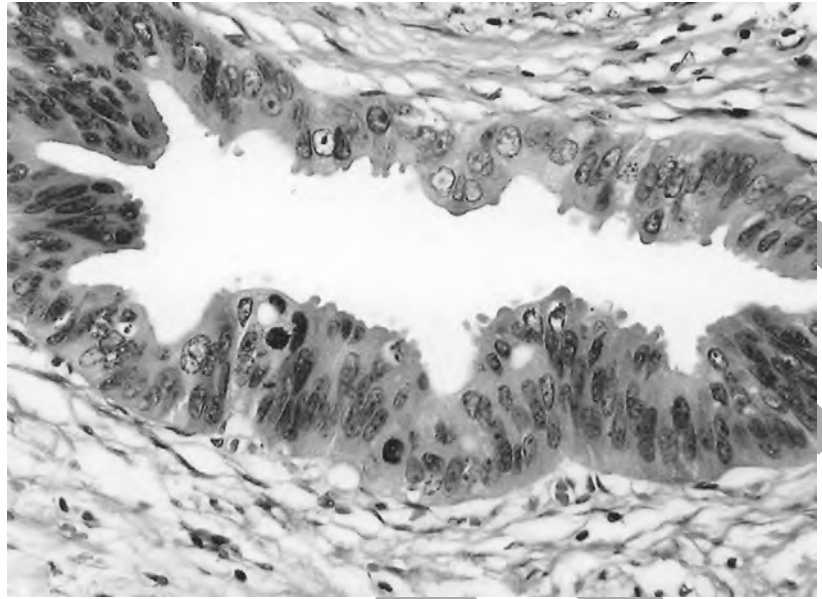


Figure 28 CGIN. There is nuclear stratification combined with nuclear enlargement and pleomorphism, focal loss of nuclear polarity, abnormal dispersion of nuclear chromatin, mitotic activity and the presence of large nucleoli in some of the cells.

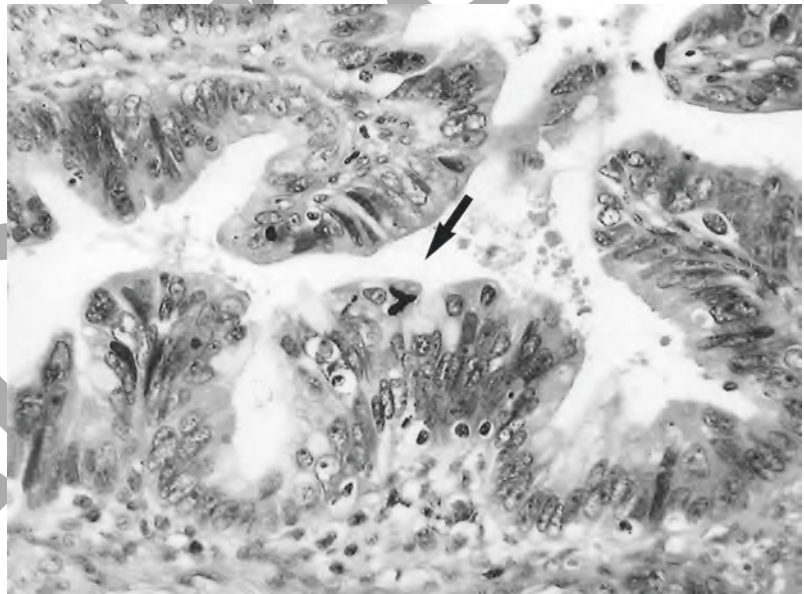


Figure 29 CGIN with an atypical mitosis.

3.1.1 *The nomenclature for CGIN*

There is, as yet, no agreed nomenclature or system of grading for CGIN. If a three-grade system is applied to CGIN, it is recognised that CGIN 3 (adenocarcinoma *in situ*) is a robust diagnosis but that there are difficulties in defining the distinction between CGIN 1 and 2. There are also difficulties in defining the most minor changes that are consistent with a diagnosis of CGIN.

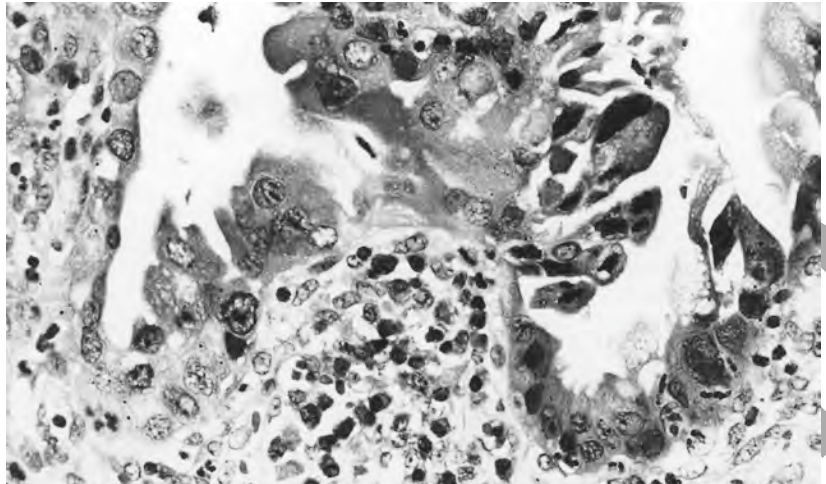


Figure 30 CGIN. Cells with a severe degree of cytological atypia. The nuclei are pleomorphic, there is loss of nuclear polarity and several nuclei contain large irregular nucleoli. Cells in the gland to the left have copious eosinophilic cytoplasm, and this should arouse a suspicion that invasion may be present. (Compare with Figures 37 and 38 and note the invasive focus from a similar epithelium in Figure 41.)

In respect of CGIN only, therefore, the following recommendations are made.

1. It is preferable, in the present state of knowledge, to recognise only two grades of CGIN. It must be emphasised, however, that this does not indicate that CGIN is a two-tier or two-stage disease but is simply a reflection of a lack of diagnostic and grading criteria.
2. The terms high-grade CGIN (CGIN 3 or adenocarcinoma *in situ*) (Figure 31) and low-grade CGIN (Figure 32), encompassing cellular abnormalities of a lesser degree,^{9,10} should be used.

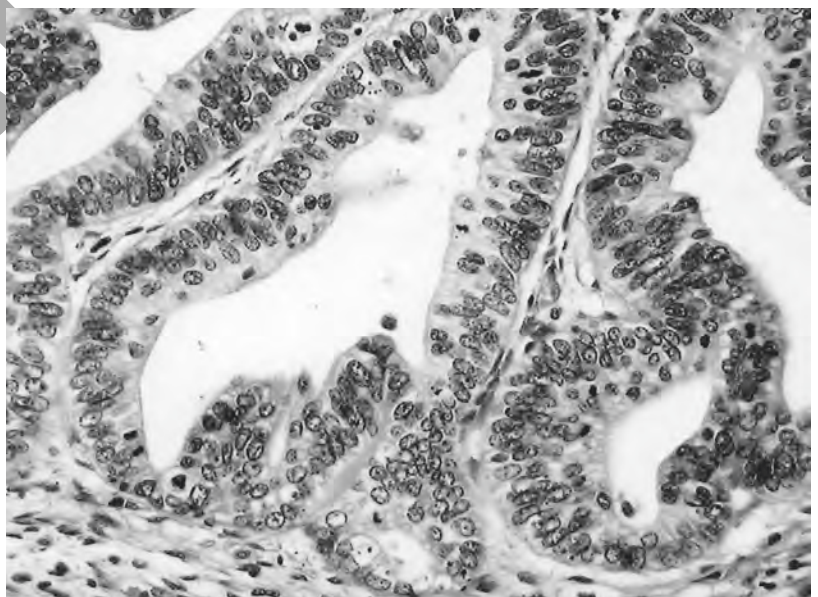


Figure 31 High-grade CGIN.

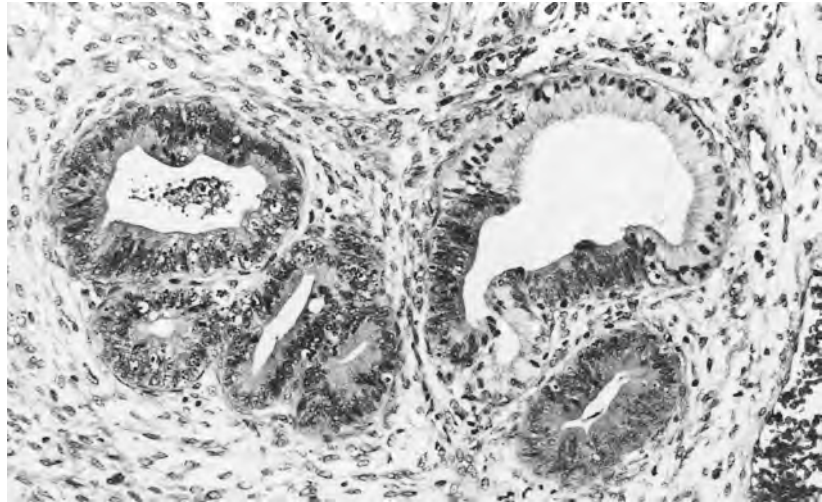


Figure 32 Low-grade CGIN.

3. The term low-grade CGIN should not necessarily be taken to indicate that there is a lesser chance of progression of the disease. This information is not available and, in our present state of knowledge, it is recommended that the clinical management of low-grade and high-grade CGIN should be the same.
4. Clinicians must be aware that, by using a diathermy loop or laser for the excision of tissue when a glandular abnormality is suspected, they may induce cellular changes that render histological interpretation difficult or impossible. There is also a higher rate of recurrence of CGIN when a diathermy loop is used compared with a cold knife cone.¹¹
5. In a cone biopsy, the pathologist making a diagnosis of CGIN can report whether or not the margins of the cone are free from disease and whether or not there is evidence of invasion. The possibility of multifocal disease – CGIN elsewhere in the remaining cervix – cannot be excluded.

3.2 Areas of diagnostic difficulty

3.2.1 High-grade CGIN or invasive adenocarcinoma

3.2.2 Endometriosis and tuboendometrioid metaplasia

Histological differentiation of high-grade CGIN from invasive adenocarcinoma may prove very difficult or impossible. Histopathologists should, wherever possible, make every effort to make this distinction, but it is recognised that there will be cases in which the pathologist remains uncertain as to whether a lesion is invasive or not, even after the mandatory examination of many levels. This must be stated in the report.

After cervical biopsy or diathermy, endometriosis or tuboendometrioid metaplasia may develop in the cervix.^{12,13} It may also occur in the absence of surgical intervention. Endometriosis (Figure 33), which is characterised by the presence of endometrium-type glands set in an endometrial stroma, most commonly occurs in the region of the external cervical os or in the lower endocervical canal. It appears at colposcopy as a haemorrhagic focus. Regular bleeding may lead to stromal fibrosis and stenosis of the external cervical os. It can usually be easily recognised histologically and, if active, is most commonly approximately in phase

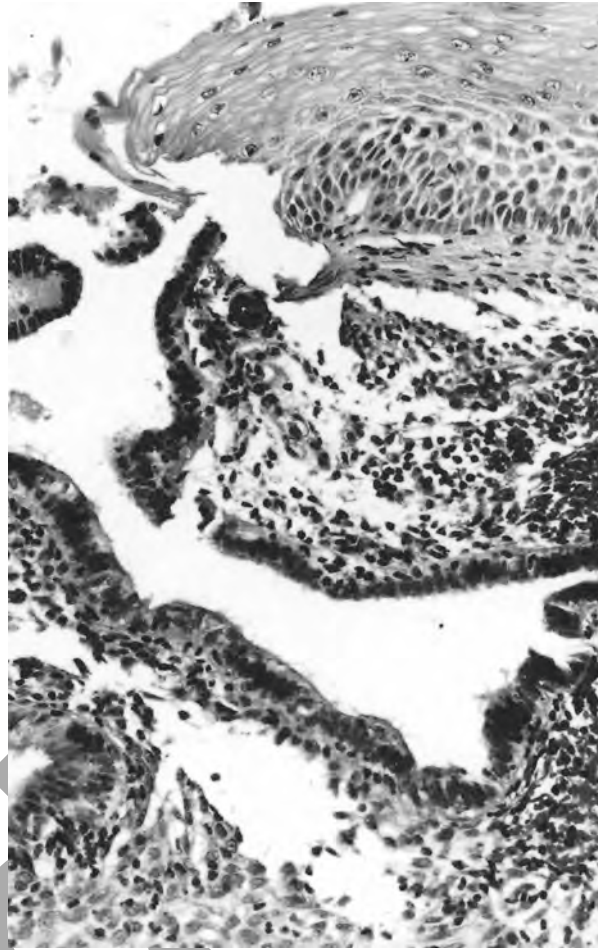


Figure 33 Endometriosis in a colposcopic biopsy. An intact, normal stratified squamous epithelium covers the surface of the biopsy, and in the underlying stroma there is a gland lined by epithelium of endometrial type, set in stroma of endometrial type. Fragmentation of such biopsies is not uncommon.

with the intrauterine endometrium. It leads to the presence in the cervical smear of endometrial cells at an inappropriate stage of the cycle, and this may give rise to the suspicion of a pathological process in the endometrium.

Tuboendometrioid metaplasia (Figure 34 and 35) is characterised by replacement of the endocervical surface or crypt epithelium by cells of typical tubal or endometrioid type or by a population of cubo-columnar cells with regular, oval to round, darkly staining, hyperchromatic basal nuclei and high nuclear–cytoplasmic ratios; some of the cells may be ciliated. Mitoses are uncommon except when oestrogen-stimulated proliferative activity is present. There is no nuclear pleomorphism and atypical mitoses are not seen (Figure 36). In cervical smears, endometrial stromal cells may be misinterpreted as severe squamous dyskaryosis. Large endometrial cell fragments of glandular and/or stromal cells or the glandular cells of tuboendometrioid metaplasia may be misinterpreted as CGIN.

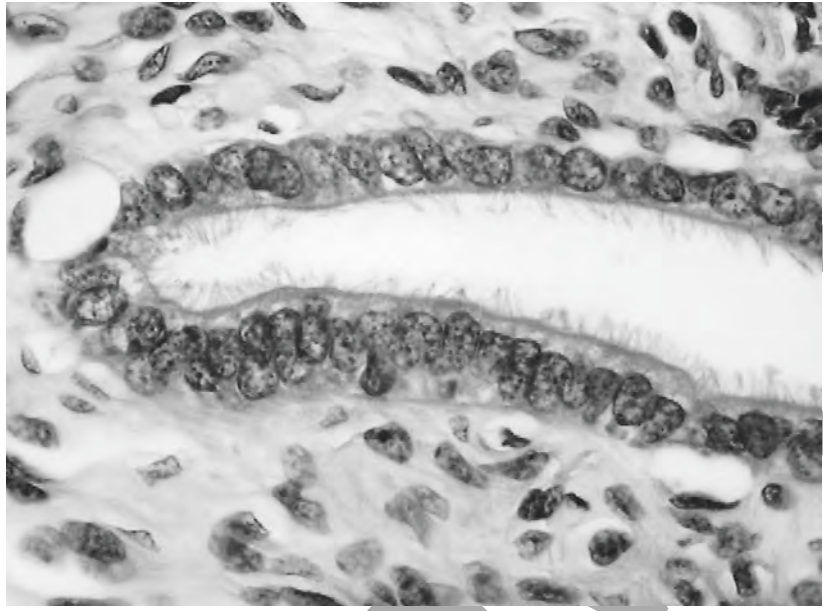


Figure 34 Tubal metaplasia in an endocervical crypt. Note the predominance of ciliated cells.

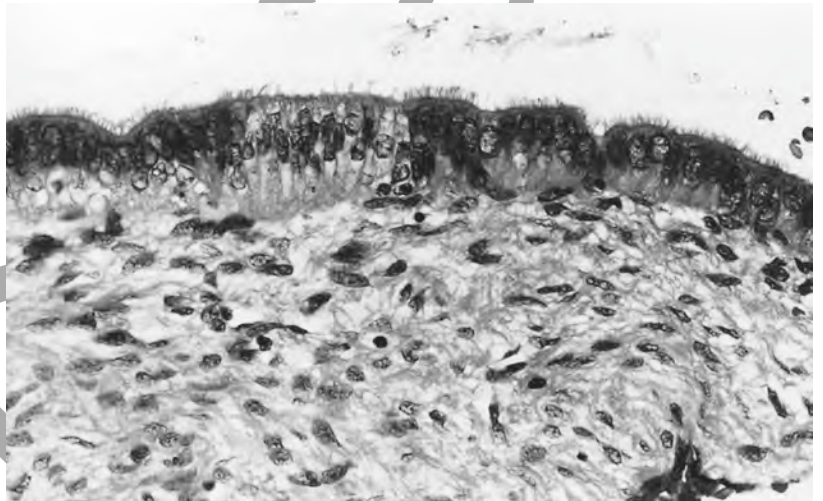


Figure 35 Tubal metaplasia. Note that tubal metaplasia may be multifocal and there may be an abrupt transition between the mucus-secreting endocervical cells and the ciliated serous cells. (Compare with Figure 36.)

3.2.3 *Progestogen-associated changes*

In women given therapeutic doses of progestogen, the endocervical columnar epithelium in the crypts, in particular, may develop a degree of stratification that may be confused with the stratification of CGIN. It can be distinguished, however, by the absence of an abrupt transition from normal to apparently abnormal epithelium and the absence of nuclear enlargement, nuclear pleomorphism and nuclear hyperchromasia; mitotic activity is not seen. The preceding cervical smear may have appeared quite normal.

3.2.4 *Inflammatory changes*

In the presence of inflammation, there is frequently a degree of nuclear enlargement in the columnar epithelium of the endocervical crypts accompanied by a reduction in the quantity of mucus secretion and hence a change in the appearance of the cytoplasm, which may become

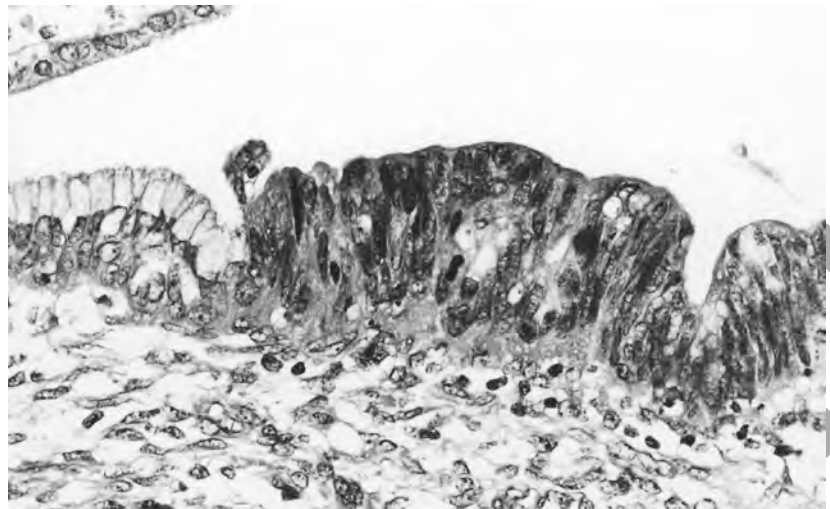


Figure 36 CGIN. Note the abrupt transition between the focus of CGIN with stratified cells and hyperchromatic nuclei and the normal endocervical cells to the left. (Compare with Figure 35.)

vacuolated, from neutral or pale blue to a more eosinophilic shade. It can be distinguished from CGIN by the absence of an abrupt transition from normal to apparently abnormal epithelium, the absence of abnormal chromatin dispersion in the nuclei, the absence of architectural abnormalities in the crypts and the presence of an active or acute or chronic inflammatory cell infiltrate in the underlying stroma which often spills over into the affected epithelium. The cervical smear may have contained abnormal glandular cells or even apparently dyskaryotic cells. Similar cytological and histological changes may be encountered in endocervical and/or endometrial cells in users of an intrauterine device.

3.2.5 *Gartner's duct remnants*

The remains of Gartner's ducts are typically to be found in the lateral deep part of the cervical stroma. On occasions, they may merge with the endocervical crypts and thus be detected in cervical smears. The structure may be represented by a series of small acini or ducts lined by cubo-columnar epithelium with high nuclear-cytoplasmic ratios but no abnormal dispersion of the nuclear chromatin; mitoses are uncommon. The lumina often contain homogeneous eosinophilic, PAS-positive, diastase-resistant material. Hyperplasia of the ducts may occur, and two forms are described: in one it is mainly the ducts which are hyperplastic; in the other the hyperplasia occurs predominantly in the acini with the development of lobules.¹⁴ On very rare occasions, transition to mesonephric carcinoma has been described.¹⁵

3.2.6 *Endocervical polyps*

Squamous cells with borderline nuclear changes may be shed either from the surface of an endocervical polyp or, as result of mechanical effects or inflammation, from the adjacent cervical surface epithelium. Keratinisation may be present. Inflammatory changes in the polyp frequently lead to columnar cell changes similar to those described in section 3.2.4. The diagnosis of a cervical polyp by the histopathologist should present no difficulties, but it is important to recognise that it may have been the source of borderline nuclear abnormalities in squamous or columnar cells in the smear.

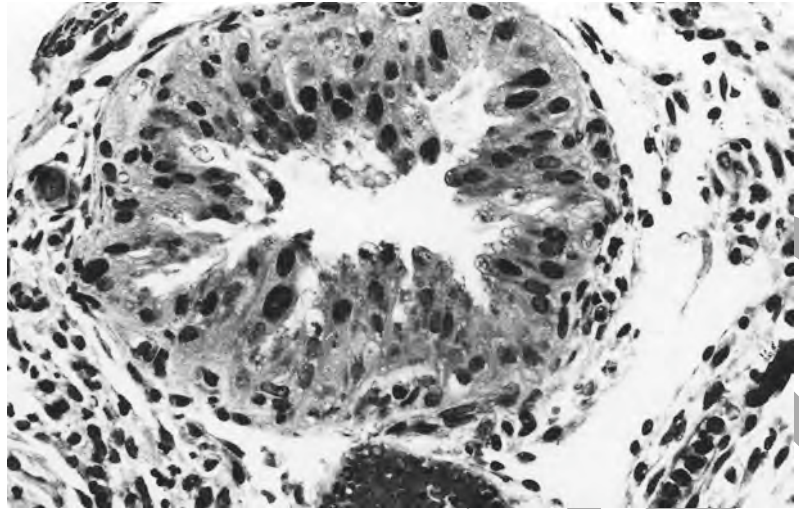


Figure 37 Arias Stella change in a cervical crypt. There is stratification of the cells and the nuclei are pleomorphic and hyperchromatic but the chromatin is not irregularly dispersed and there is no mitotic activity.

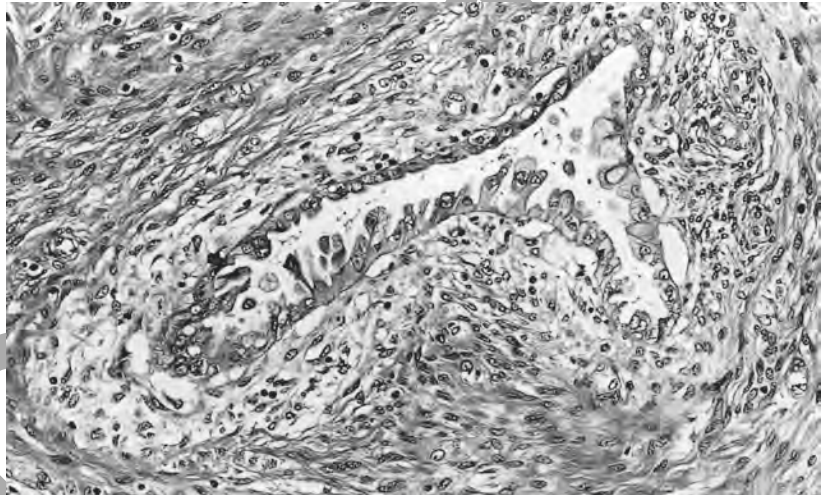


Figure 38 Arias Stella change in a cervical crypt. The nuclei, which are enlarged and have lost their polarity, lie at the apices of many of the cells, creating a hobnail appearance. There is a weak decidual change in the surrounding stroma which may mimic a desmoplastic response. (Compare with Figures 30 and 41.)

3.2.7 *Arias Stella change*

In pregnancy, Arias Stella change similar to that seen in the endometrium may also occur in the cervical crypt epithelium (Figures 37 and 38). The cells in the crypt epithelium are rounded and characteristically have large nuclei, which tend to lie at the tip of the cell, creating a hobnail-like appearance; the cytoplasm is often vacuolated or eosinophilic. The nuclei are large and often hyperchromatic and the chromatin unevenly dispersed. The presence of Arias Stella change in a cervical smear can sometimes give rise to diagnostic difficulties.

3.2.8 *Microglandular hyperplasia*

The superficial or polypoidal masses of small, closely packed glandular acini which constitute microglandular hyperplasia are often lined by a stratified epithelium of cubo-columnar type, but foci of reserve cell

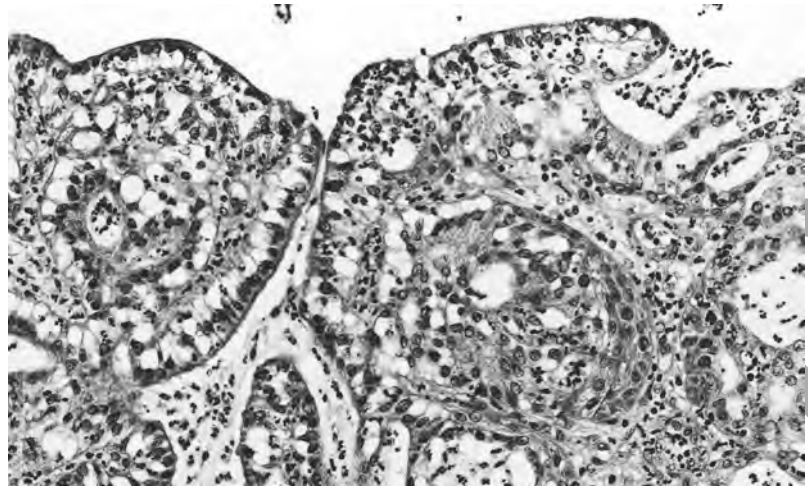


Figure 39 Microglandular hyperplasia. There is a mixture of small glandular acini and foci of immature squamous metaplasia. The cytoplasm of the columnar cells is vacuolated and the tissue is infiltrated by polymorphs.

hyperplasia and immature squamous metaplasia are common. Histological distinction from carcinoma is usually straightforward (Figure 39) but its presence may be an explanation for abnormalities in the cervical smear.

4. MICROINVASIVE CARCINOMA

Microinvasive carcinoma of the cervix uteri is, by definition, a histological diagnosis, and such a neoplasm is believed to carry little or no risk of metastatic disease. It can therefore usually be treated relatively conservatively. Although this statement holds true for most tumours in this category, a small number of, generally larger, microinvasive carcinomas may progress to metastatic disease.¹⁶

In the UK, the term microinvasive carcinoma is taken as being synonymous with FIGO stages IA1 and IA2, whereas in the USA the term is synonymous only with stage IA1.¹⁷ It must be emphasised, however, that the term microinvasive carcinoma does not appear in the FIGO staging announcements though it is in common usage and is well understood by pathologists and gynaecologists (Table 1). The report on such lesions should state that the lesion that has been identified is consistent with FIGO stage IA and not simply that it is microinvasive as this is insufficiently precise to allow the surgeon to plan management.

Invasive lesions included in stage IA1 are up to 7 mm in horizontal axis and 3 mm or less in depth measured from the base of the epithelium from which they arise. An invasive lesion measuring up to 7 mm in horizontal axis and between 3.1 and 5 mm in depth from the base of the epithelium from which it arises is included in stage IA2 (Table 2). The staging announcement does not provide guidance on whether tumours exactly 3 mm deep should be included in stage IA1 or IA2 and, until there is advice to the contrary, it is recommended that lesions 3 mm in depth should be included in stage IA1. Tumours which lie between 3.1 mm and 5 mm deep (including tumours measuring exactly 5 mm deep) should be included in stage IA2.¹⁶

Table 1 FIGO staging of cervical carcinoma (1988)

Stage	
0	CIN
I	Carcinoma strictly confined to the cervix*
IA	Preclinical – detected only by microscopy
IA1	Minimal microscopically evident stromal invasion
IA2	Lesions that can be measured: depth should be no greater than 5 mm Horizontal spread must not exceed 7 mm. Larger lesions are stage IB**
IB	Lesions greater in size than stage IA2 whether seen clinically or not. Preformed space involvement does not alter the staging but should be recorded to enable future evaluation of its significance to be determined

*Extension to the corpus is ignored.

**Depth of invasion is measured from the base of the epithelium, either surface or crypt, from which invasion occurs.

After Shepherd.²²

Table 2 FIGO staging of cervical carcinoma (1995)

Stage	
I	Carcinoma strictly confined to the cervix*
IA	Lesions detected only microscopically. Maximum size 5 mm deep and 7 mm across.** Venous or lymphatic permeation does not alter the staging***
IA1	Invasion of stroma to a maximum of 3 mm.** Horizontal axis 7 mm or less
IA2	Invasion of stroma greater than 3 mm but no greater than 5 mm.** Horizontal axis 7 mm or less
IB	Clinically apparent lesions confined to the cervix or preclinical lesions larger than stage IA allows
IB1	Clinical lesions no greater than 4 cm in size
IB2	Clinical lesions greater than 4 cm in size
II–IV	Remain the same

*Extension to the corpus is ignored.

**Depth of invasion is measured from the base of the epithelium, either surface or crypt, from which invasion occurs.

***All gross lesions even those with only superficial invasion are stage IB.

After Shepherd.¹⁷

The presence of lymphatic or vascular permeation in the vicinity of the neoplasm must be carefully and regularly recorded in the histopathological report, but its presence does not alter the staging of the neoplasm. Despite the fact that the FIGO staging announcements state that stage I tumours are limited to the cervix, extension of larger neoplasms to the body of the uterus does not affect the staging.

4.1 Histological features of microinvasive carcinoma

Histologically, microinvasive carcinoma takes two forms. The first, previously termed early stromal invasion (ESI), consists of single or multiple tongues of atypical epithelium, generally showing a greater degree of cytoplasmic maturation and cytoplasmic eosinophilia than the epithelium from which they arise, infiltrating the stroma from the base of an epithelium in which there are features of CIN or CGIN (Figures 40 and 41). A loosening of the stroma at the point of penetration and a round cell infiltrate usually accompany the invasion. Such lesions may be difficult to measure but lie no more than 1 mm from the epithelium of origin. The measured diameter of such lesions should encompass all the foci of invasion in the immediate area. It needs to be remembered that if the invasive foci are seen in three or more blocks of tissue, the diameter of the lesion may exceed 7 mm. Squamous lesions of this type are not uncommon. Early stromal invasion of adenocarcinomatous type is, however, uncommon.

The second type of microinvasive carcinoma is a small confluent tumour. It may be squamous carcinoma (Figure 42), adenocarcinoma (Figure 43) or adenosquamous carcinoma. The cells in the microinvasive squamous carcinoma usually, but not invariably, show a greater degree of cytoplasmic maturation than does the associated CIN. The pathologist

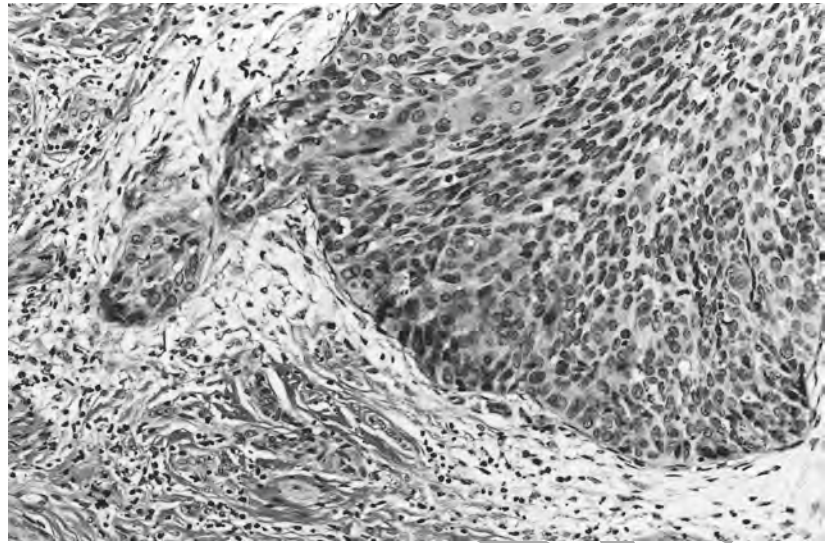


Figure 40 Microinvasive squamous cell carcinoma (previously known as early stromal invasion: FIGO IA1). A cervical crypt, to the upper right, is lined by an epithelium with the features of CIN3. An invasive focus arises from its base. Note the loosening of the stroma and the lymphocytic infiltrate. (See Figure 44.)

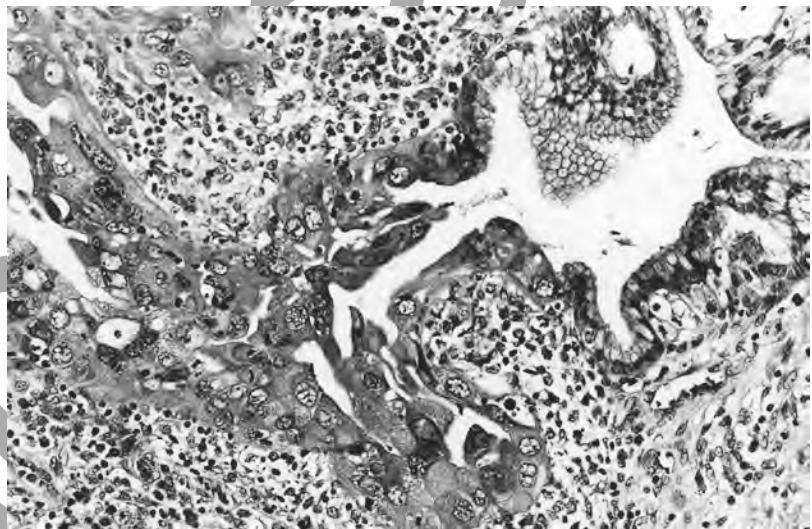


Figure 41 Microinvasive adenocarcinoma. (FIGO IA1) The cervical crypt to the right is lined partly by an epithelium with the features of CGIN. To the left, there is a change in the character of the cells. The nuclei are larger and more pleomorphic and the cytoplasm is paler and more copious, with cytoplasmic eosinophilia. There is a focus of invasion arising from the lower border of the crypt and there are invasive foci in the upper left part of the field. Note the stromal lymphocytic infiltrate.

must distinguish a small squamous carcinoma from endocervical crypts distended by CIN (Figure 44), and in the majority of cases this should not prove difficult.

CGIN should, and can, be distinguished from microinvasive adenocarcinoma in most cases by its limitation to the glandular field, by

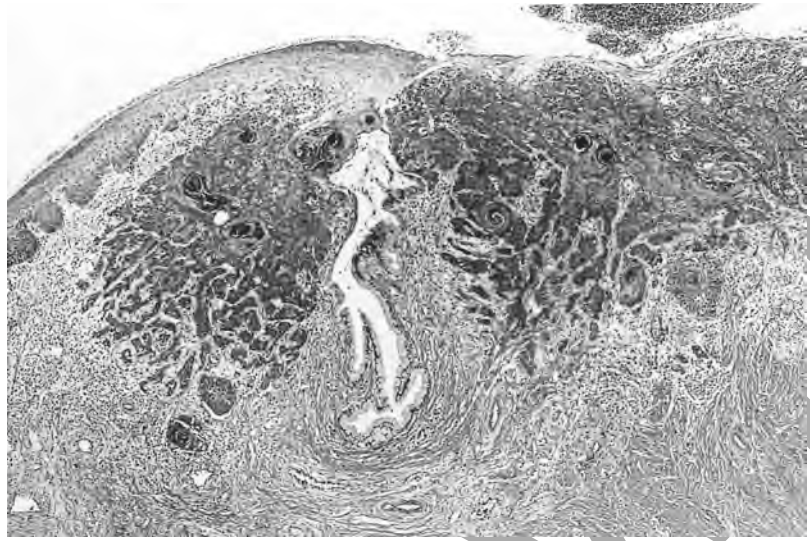


Figure 42 Microinvasive squamous cell carcinoma. A small confluent squamous cell carcinoma.



Figure 43 Microinvasive adenocarcinoma. A small confluent, poorly differentiated adenocarcinoma.

the constant admixture of neoplastic and normal glands and by the lack of stromal response (Figure 45).⁸ Problems in distinguishing high-grade CGIN from adenocarcinoma occur, particularly in biopsies in which groups of closely packed, architecturally abnormal glands are lined by an epithelium, fulfilling the criteria for CGIN. Features suggesting that stromal invasion has occurred include increased cytoplasmic eosinophilia, the presence of a back-to-back arrangement of the atypical glands, a desmoplastic stromal response and an inflammatory cell infiltrate (Figure 46). Invasive neoplasia must not be excluded on the basis of a punch biopsy, and whenever possible a cold knife cone biopsy should be obtained for fuller evaluation.

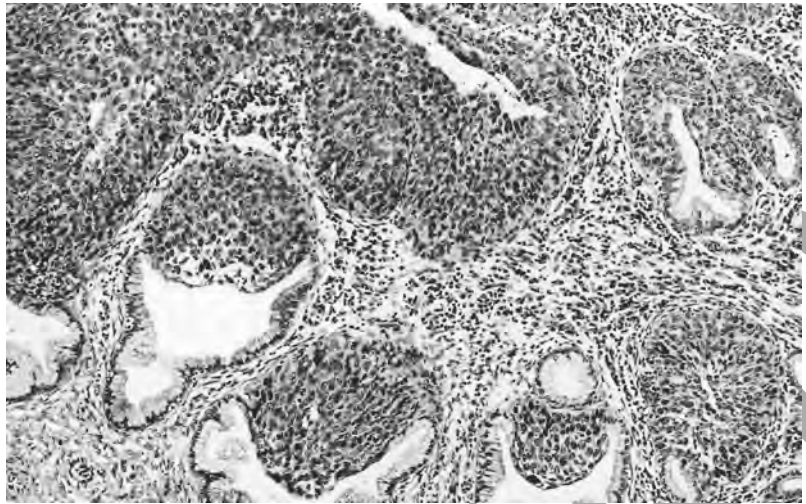


Figure 44 Endocervical crypts distended by an epithelium with the features of CIN3. Contrast the smooth margins of the crypts and the absence of stromal loosening with the jagged shape of the infiltrative focus and stromal response in Figure 40.

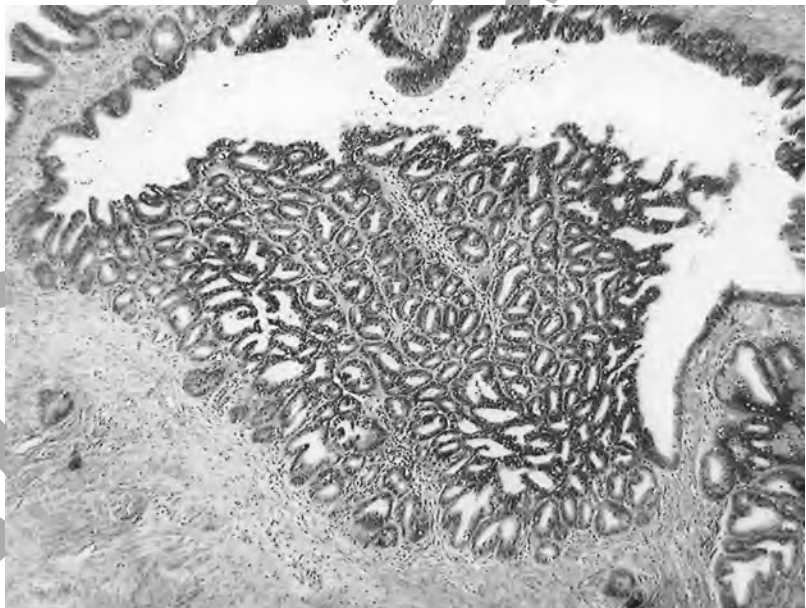


Figure 45 A collection of small glandular acini in a cervix in which there is high-grade CGIN, which raises the suspicion of microinvasive adenocarcinoma. Note the absence of stromal response. This is not invasive.

The measurement of confluent microinvasive carcinoma is identical whether the lesion is squamous carcinoma or adenocarcinoma. It should be measured from the point of deepest invasion to the base of the epithelium from which invasion has occurred. In the event that the intraepithelial source cannot be determined, measurement should be made from the nearest crypt or surface epithelium in which there are features of intraepithelial neoplasia.

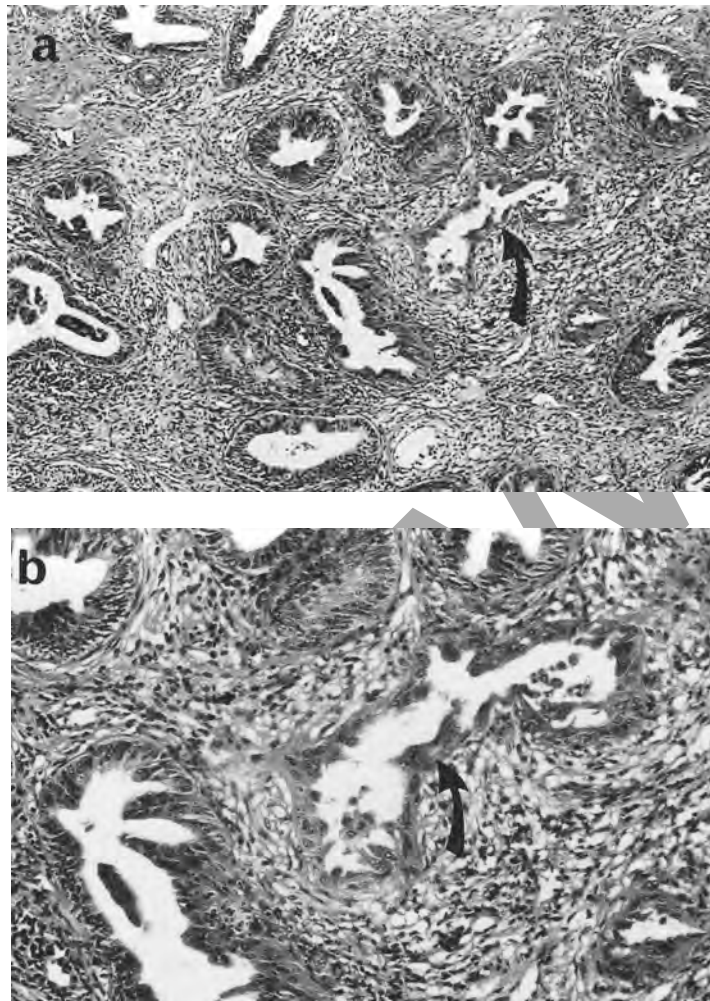


Figure 46 A collection of small glandular acini lined by an epithelium with the features of high grade CGIN, a lesion which superficially resembles Figure 45 (a). Note, however, (b) the stromal response to the gland in the centre of the field (arrow). This is evidence of stromal invasion.

4.2 Reporting of microinvasive carcinoma

With respect to microinvasive carcinoma, the following points are emphasised:

1. The nature of the invasive lesion should be described, for example as a small confluent tumour or invasion limited to small, non-confluent tongues of invasion (so-called early stromal invasion).
2. The depth of the tumour is measured from the base of the epithelium from which it arises.
3. If there is no obvious epithelial source, the depth should be measured from the base of the nearest intact epithelium.
4. On the rare occasions when the surface of a small carcinoma is ulcerated, it is impossible to determine how much tissue has been lost. Such lesions must not be called microinvasive.
5. The width of the tumour should be measured in the section in which the width is greatest.
6. Where a microinvasive carcinoma reaches the cervical surface, it is measured from its surface to the point of deepest invasion.
7. Where a small confluent tumour does not reach the surface, the

tumour size should be determined in two dimensions to encompass the whole lesion.

8. The width of a lesion is measured from the edge at which invasion is first seen to the most distant edge at which invasion can be detected. The measurement of width is not limited to the confluent component.
9. The term microinvasive carcinoma should not be applied to small cell (neuroendocrine) tumours or peripheral neuroectodermal tumours (PNETs) of the cervix no matter how small the lesion. Such tumours should not be treated conservatively.
10. In our present state of knowledge, we cannot define precisely a glandular lesion that is equivalent to stage IA1 and can only call it a small carcinoma.
11. Care must be exercised in drawing a parallel among squamous lesions that are encompassed by FIGO stage IA1 and IA2 and adenocarcinoma of apparently similar size because the experience gained in the treatment of microinvasive adenocarcinoma is limited, though early reports suggest that it may be possible to apply similar treatment protocols.¹⁸ It is important, therefore, that the size of these small adenocarcinomas should be carefully recorded so that outcomes can be related to tumour size.
12. Microinvasive carcinoma cannot be diagnosed on a punch biopsy. The diagnosis can be made only in a cone or loop biopsy that includes the whole of the lesion (as such lesions may be multifocal), and in which the margins are free from intraepithelial and invasive neoplasia. If these criteria are not fulfilled, the histology report should simply state that the lesion in the available tissue is within the definition of FIGO stage IA but that CIN or CGIN reaches the margin and the possibility of further invasive disease cannot be excluded.
13. In all reports, the presence or absence of vascular permeation must be recorded.

5. INVASIVE CARCINOMA

The amount of information that can be provided in a histopathology report will depend upon the nature of the biopsy on which the diagnosis has been made.

In all cases, the histopathologist must, wherever possible:

- classify the tumour
- grade the tumour
- give the size of the lesion
- comment on the presence or absence of vascular invasion (invasion of blood vessels and lymphatics).

Where the biopsy includes the whole of the carcinoma, the tumour should be measured and the adequacy of excision be described.

5.1 Classification of invasive carcinoma

The classification given in Table 3 is recommended.¹⁹⁻²¹

Ideally, mucin stains (PAS/Alcian blue) should be carried out on all cervical carcinomas as this is the only way that poorly differentiated adenocarcinomas and adenosquamous carcinomas can be identified. It is also recommended that a diagnosis of squamous cell carcinoma should be made only in the absence of intracytoplasmic mucin. The presence of widespread intracytoplasmic mucin requires a diagnosis of adenocarcinoma, and any intracytoplasmic mucin (even in a tumour showing clear evidence of squamous differentiation) demands a diagnosis of adenosquamous carcinoma. Mucin secretion may be limited to one part of a neoplasm or to its infiltrating margin. The search for mucin in microinvasive carcinomas is left to the individual pathologist but is not regarded as essential.

5.2 Grading of cervical carcinoma

Opinion varies as to the significance of grading of cervical tumours, and grade is unlikely to affect the mode of treatment of a particular neoplasm. Tumours should, however, be graded to permit:

- the establishment of an accurate database
- correlation with cervical smears
- the detection of variations in prognosis that might stem from differences in tumour differentiation.

Grading is required for the registration of cervical cancers (see Appendix 2).

5.2.1 Grading of squamous cell carcinoma

Two systems of nomenclature are in use for grading cervical squamous cell carcinomas. Both are basically descriptive, and at present there is no objective system in common use. The descriptive systems are as follows:

Well differentiated

Large cell keratinising squamous cell carcinoma

Histopathology Reporting in Cervical Screening

Table 3 The classification of malignant cervical neoplasms

ICD-10 code	
8070/3	Squamous cell carcinoma
8071/3	Invasive large cell keratinising
8072/3	Invasive large cell non-keratinising
8073/3	Invasive small cell non-keratinising
8051/3	Verrucous carcinoma
8090/3	Adenoid basal carcinoma
8140/3	Adenocarcinoma
8480/3	Mucinous adenocarcinoma
8140/3	Endocervical type adenocarcinoma
8140/3	Minimal deviation adenocarcinoma
8260/3	Papillary including villo-glandular adenocarcinoma
8144/3	Intestinal adenocarcinoma
8490/3	Signet ring adenocarcinoma
8380/3	Endometrioid adenocarcinoma
8310/3	Clear cell adenocarcinoma
8200/3	Adenoid cystic adenocarcinoma
8441/3	Serous adenocarcinoma
9110/3	Mesonephric adenocarcinoma
Mixed epithelial tumours	
8560/3	Adenosquamous carcinoma
8200/3	Adenoid cystic carcinoma
8041/3	Small cell carcinomas
8246/3	Neuroendocrine tumours
Mixed epithelial/stromal tumours	
8933/3	Adenosarcoma
8980/3	Carcinosarcoma
	Carcinofibroma
8890/3	Stromal neoplasms
8930/3	Endometrial stromal sarcoma
8890/3	Leiomyosarcoma
8900/3	Rhabdomyosarcoma
8000/3	Other

Further advice on the classification and grading of cervical neoplasms is included in references 6, 19, 21 and 46.

Moderately differentiated	Large cell focally keratinising squamous cell carcinoma Large cell non-keratinising squamous cell carcinoma
Poorly differentiated	Small cell non-keratinising squamous cell carcinoma

In practice, individually keratinising cells will be seen in the so-called non-keratinising carcinomas, and without the presence of at least abortive evidence of squamous differentiation the tumour must not be classified

as squamous carcinomas simply by default. Such tumours should be described as undifferentiated carcinomas. Small cell squamous carcinomas must be carefully distinguished from small cell neuroendocrine tumours, for which different treatment protocols are used.

5.2.2 *Grading of adenocarcinoma*

There is no agreed system of grading adenocarcinoma, and it is suggested that a system similar to that currently employed for endometrial carcinoma should be employed. This combines architectural and cytological criteria.²² The solid areas of a poorly differentiated adenocarcinoma should be non-squamoid, and the presence of intracytoplasmic mucin should have been confirmed histologically. Endometrioid adenocarcinoma may contain areas of apparently benign squamous differentiation: this does not mean that the tumour has to be reclassified as an adenosquamous carcinoma. Clear cell adenocarcinoma is graded only on the nuclear features.²³ Villoglandular carcinoma should be recognised and reported as such because the prognosis of these tumours is good.

5.2.3 *Grading of adenosquamous carcinoma*

It is a matter of debate as to how adenosquamous carcinoma should be graded. The following guidelines are offered:

Well differentiated

Glandular differentiation in 95% or more of the adenocarcinomatous element combined with either large cell keratinising squamous carcinoma or large cell focally keratinising squamous cell carcinoma

Moderately differentiated

Glandular or acinar differentiation in 50–94% of the neoplasm but with easily identifiable acini combined with any grade of squamous cell carcinoma

Poorly differentiated

Adenocarcinomatous differentiation in 49% or less of the neoplasm or recognisable only by the presence of intracytoplasmic mucin combined with squamous cell carcinoma of any degree of differentiation

5.3 **Measurement of cervical carcinoma**

The system of measurement is identical with that described in section 4 on microinvasive carcinoma. It is more likely, however, that only part of a larger carcinoma will have been identified in a loop or cone biopsy and the pathologist may be limited to providing the maximum dimension of the tumour present in the biopsy, combined with a statement that the tumour exceeds that encompassed by the guidelines for FIGO stage IA and has not been completely removed.

6. ADVICE ON THE REPORTING OF BIOPSIES

1. The report should include a full naked-eye description of the specimen which incorporates the size, state and nature of the specimen except in the case of punch biopsies, when the naked-eye description is of limited value. The number of pieces in which a loop biopsy is received should be recorded, as should the completeness or otherwise of a cone biopsy. A photograph or computer image is useful in providing a permanent record and to allow the position of the blocks to be recorded.
2. The report must identify the nature of the tissue. Where fragmentation of the tissue, surgical/operative trauma, coagulation artifact or loss of epithelium hinders interpretation of the biopsy, this must be clearly stated in the report. An indication should be given as to the nature of the limitation, for example whether the epithelium is lost at the resection margins or the epithelium is coagulated or absent.
3. In preparing the report, the histopathologist must bear in mind the need to correlate the findings with the previous cytological report. All pathological lesions and non-neoplastic histological features that may be associated with cytological abnormalities should therefore be included in the histological report.
4. A clear distinction must be made between a specimen that fails to identify the source of the abnormal cells in the smear because it is technically unsatisfactory or damaged and a biopsy that is technically satisfactory but still fails to identify the lesion.
5. All grades of squamous and/or glandular intraepithelial neoplasia present should be reported and invasive lesions classified and graded.
6. Koilocytosis and koilocytosis-associated changes should be consistently reported but, unless the CIN is represented by only a small focus in a lesion in which koilocytosis-associated changes predominate, the CIN should be mentioned first.
7. In the case of loop biopsies or cone biopsies, the report must indicate whether the abnormal squamous epithelium has been completely excised. Care should be exercised in reporting loop biopsies received in several pieces as it is often impossible to confirm that the lesion has been completely removed.
8. A report on a punch biopsy in which there is CGIN must carry a rider stating that the possibility of invasion cannot be excluded from the biopsy. Even in a cone biopsy, though the pathologist making a diagnosis of CGIN can report whether the margins of the cone are free from disease, and whether there is evidence of invasion, there can be no guarantee that there will not be further foci of disease.

9. There will be cases in which the pathologist will be uncertain whether the lesion is invasive even after examination of many levels, and this should be stated in the report.
10. A report of microinvasive carcinoma must not be made on a punch or wedge biopsy. It can be made only on a cone/loop biopsy in which the whole of the invasive and intraepithelial lesion has been removed and the margins of the tissue are free from disease.
11. A report of a microinvasive carcinoma must give the measurements of the invasive lesion and indicate the FIGO stage to which this measurement equates. A calibrated eyepiece graticule is ideal for the purpose as it can be rotated to facilitate measuring.
12. A report of a carcinoma which is larger than that encompassed by FIGO stage I must include the following information:
 - when the entire tumour is included in a cone biopsy or loop biopsy, it must be measured and a statement made that the carcinoma exceeds the size allowed in FIGO stage A1
 - when only a sample of the tumour has been sent, the report must indicate that this is only part of the lesion
 - in all cases, the report must address the type of tumour, its differentiation and the presence or absence of vascular permeation.
13. In a hysterectomy specimen in which a cervical neoplasm is expected, the cervix should be removed, blocked as if it were a cone biopsy and examined in its entirety. It is also important, in respect of CGIN or in patients who have previously had a cervical intraepithelial neoplasm treated, to examine the upper endocervical canal and uterine isthmus to detect discontinuous lesions. The histological reports should follow the form recommended for cone biopsies and loop excisions. Additional advice on the handling of Wertheim's hysterectomies can be obtained from the Association of Clinical Pathologists (ACP) broadsheet.²⁴
14. Adopting a technique for the examination of the cervix that allows the histopathologist to return to the specimen is recommended so that, if a hysterectomy specimen reveals an unexpected cervical intraepithelial neoplasm or carcinoma, the remainder of the tissue can be accurately serially blocked. The routine removal of the cervix from the uterus prior to opening the corpus uteri and taking a block from the mid anterior and mid posterior lips allows the residual cervix to be subsequently serially blocked to determine the extent and nature of the neoplastic process.
15. The reporting of cervical biopsies has been considered as part of the NHS clinical messages development programme which is concerned with the electronic transfer of data. Further details of the work in progress are given in Appendix 3.

7. AUDITING AND QUALITY ASSURANCE

7.1 Internal review of cytological and histological findings

The cervical biopsy and subsequent histological examination should explain the cytological findings, and the biopsy and the cervical cytology must be correlated routinely in every case. All laboratories undertaking histology and cytology must be fully compliant with the recommendations in the *Quality Assurance Guidelines for the Cervical Screening Programme*.²⁵ Where there is a discrepancy in the findings (that is, the cervical smear findings and the histological findings do not match), an explanation must be sought. Some of the discrepancies will be significant, but others are minor and of no practical importance. The situations described below may occur.

7.1.1 *Histological findings more severe than those suggested by the cytological findings*

Cervical cytology will underestimate the degree of abnormality actually present on the cervix in a significant minority of cases. This is usually due to sampling error and unless, for example, persistent undersampling can be demonstrated (by appropriate audit) and attributed to a particular smear taker it does not indicate a remediable problem. The cervical smear must always be regarded as indicating the *least* abnormality that may be expected in the biopsy.

A small proportion of cytological false negatives are unavoidable, but nevertheless it must be recognised that errors of cytological interpretation may result in significant undergrading of smear abnormalities.²⁶ Occasionally, such undergrading may result in delay in management of individual patients. This may occur in the following circumstances:

- failure simply to recognise dyskaryotic cells, or failure to recognise dyskaryotic cells of high grade by confusing them with inflammatory nuclear changes ('pale' dyskaryosis is a particular pitfall, especially when the cells are small)^{6,27,28}
- failure to recognise CGIN
- failure to recognise a smear background with inflammatory cells, blood staining and debris, sometimes referred to as a 'malignant diathesis'
- on occasion, an invasive carcinoma may be detected histologically when the smear has contained no severely dyskaryotic cells, though lesser degrees of abnormal cells from associated CIN are present; rarely a smear from a cervix with invasive carcinoma may be genuinely negative.

Where undergrading has occurred the course of action is as follows:

- the cytological findings must be checked; if they prove to have been incorrectly reported, the problem must be examined and rectified
- repeated undersampling needs to be rectified by ensuring that the people taking the cervical smears understand the technique fully
- further action is not always indicated; the detection of microinvasive carcinoma should not necessarily be regarded as a failure of the screening programme

7.1.2 *Histological findings less severe than was expected on cytology*

- review of all previous available cytology is mandatory when invasive carcinoma is detected.

This may occur in a variety of circumstances and must be thoroughly investigated by the cytopathologist and histopathologist and, if necessary, the colposcopist. Problems may be associated with any of the three components of the procedure.

Cytology. There has been a false positive or 'overcall' report. This may occur in the following circumstances:

- degenerate metaplastic cells have been misinterpreted as dyskaryotic normal small cell types, e.g. endometrial cells, histiocytes or lymphoid cells in follicular cervicitis have been misinterpreted as severe squamous dyskaryosis
- sheets of parabasal squamous cells may have been misinterpreted as severely dyskaryotic in an atrophic smear.

Histology

- there is a loss of epithelium from the surface of the biopsy
- there is coagulation artifact and interpretation is hindered
- the tissue block(s) may need to be cut deeper.

Colposcopy

- the colposcopist has not chosen the most appropriate site to biopsy.

The course of action if the histological findings are less severe than was expected are as follows:

- unless it is clear from the poor quality of the biopsy that correlation is unlikely, the previous abnormal smear(s) must be critically reviewed
- in cases which are not straightforward, it would be helpful for the smear and the biopsy material to be reviewed by another pathologist, and in cases of exceptional difficulty referral to a recognised expert pathologist in the field may be appropriate
- the reasons for the failure of the smear to predict the apparent outcome should be analysed and any faults remedied
- where the smears are held in a different laboratory, a joint audit of the previous findings must be undertaken
- if it is agreed that the cytological findings are correct, the smear and biopsy must be reviewed together to see if an explanation for the discrepancy can be found or if an alternative histological abnormality, other than that which had been anticipated from the cytological findings, can be found to offer an explanation (for example, cells previously reported as severely dyskaryotic may be explained by the presence of endometriosis, or cells suggestive of CGIN may be explained by the presence of tuboendometrioid metaplasia)
- if it is agreed that there is an unexplained cytological finding, and a technically satisfactory biopsy has been obtained, it is important that the gynaecologist and/or colposcopist recognise that they have not found the source of the abnormal cells in the smear.

7.2 Routine auditing of histopathology

It is recommended that the following procedures must be part of the laboratory routine:

- the timeliness of the report should be monitored.
- reports should be audited against the recommendations in this document to ensure that they contain all the points described in Chapter 6.
- good practice also requires that a percentage of cases reported as CIN, CGIN, microinvasive carcinoma or carcinoma, selected at random to include all pathologists reports, should be reviewed by their colleagues to ensure uniformity in the interpretation of diagnostic criteria
- as in all audit, the changes made as a consequence of the above procedures should be assessed to ensure that a beneficial result has been achieved.

Further information on quality assurance in cytopathology is included in *Assuring the Quality and Measuring the Effectiveness of Cervical Screening and Achievable Standards, Benchmarks for Reporting and Criteria for Evaluating Cervical Cytopathology*.^{29,30}

8. CLINICAL IMPORTANCE OF THE PATHOLOGICAL DIAGNOSIS

It is not the remit of this document to provide guidelines on the management of cervical intraepithelial and invasive neoplasia. It is appropriate, however, to review briefly the clinical consequences and clinical importance of the diagnoses.

The histological diagnosis must be taken in the context of the cytological findings. It is inappropriate to ignore abnormal cytological findings, and every effort must be made to explain satisfactorily a confirmed cytological abnormality in the presence of persistent normal histopathological findings. It is, in general terms, preferable for different pathologists to report the cervical smears and the biopsies from the same patient. This is of particular importance in reference to the correlation of screening smears but is less important for smears taken as part of the diagnostic process. It is also important to remember that the FIGO guidelines are meant to permit a comparison among the behaviour of tumours staged according to the guidelines, and are not intended as guidelines for the management of cervical carcinoma. In practice, however, the FIGO stage frequently forms the basis of management decisions.

8.1 Linking clinical and pathological work

Referral to a gynaecologist for colposcopic evaluation of a patient with an abnormal smear must be accompanied by a copy of the cytology report precipitating the clinical referral if the referral is to a different hospital from that at which the cytology was reported. Clinicians have an obligation to provide the cytopathologist and the histopathologist with all relevant clinical information. This includes previous cytology reports if carried out in a different laboratory, previous histological findings, clinical findings and knowledge of previous therapy to the cervix.

At the time of reporting a cervical biopsy in the context of the cervical screening programme, access to the cytology report is mandatory so that the report can be prepared in full knowledge of the cytological findings. Access to the cervical smear is also strongly recommended. This is not always possible, though ideally the cytology, histopathology and colposcopy should take place where there is a close clinical relation among disciplines. This is facilitated by their being in close geographical proximity.³¹ Additionally, the reports of any previous cervical biopsies should be available to those responsible for the reporting of cervical smears from a particular patient. It is also important that histology reports are made available to cytologists even when the screening smear is negative.

Ideally, the cervical biopsies and the cervical cytology should be reported in the same laboratory. Correlation of results will be aided by computer systems set up so that a complete, chronologically arranged, integrated smear and biopsy record is available for an individual patient. This may

frequently not be achieved, particularly in metropolitan areas where numerous cross-boundary referrals occur. These will, however, often occur in recognisable patterns, and appropriate communications should be set up according to local requirements. Where the cytology and histology is reported in different laboratories, on-line access to the data in both centres is strongly recommended. It is also good practice in both histopathology and cytopathology for slides to be made readily available to other laboratories on request when review is considered necessary.

Histopathology reports must be made available not only to the clinician responsible for the patient, but also to the cytology laboratories that reported the original and diagnostic smears (if not the same). This is of particular importance when the preceding smear was reported as negative and the cytology laboratory will not have made an enquiry on a failsafe basis. Every effort must be made to ensure that cytology laboratories are made aware of unexpected findings in patients for whom they have previously issued negative reports. This responsibility falls on the referring specialist clinician or general practitioner when the patient is treated elsewhere, such as in tertiary referrals.

8.2 Cervical squamous intraepithelial neoplasia

CIN is usually treated by local ablation or excision unless there are clinical indications to the contrary. The rationale for this form of treatment is that a diagnosis of primary CIN means that, in the vast majority of cases, the gynaecologist is dealing with a continuous area of intraepithelial neoplasia in the transformation zone. Provided that the pathologist is certain that the resection margins of the biopsy are free from disease, it can be assumed that the whole lesion has been removed.

There are three important factors for future management:

- treatment that fails to remove the whole of the lesion may result in the patient's having more than one focus of residual CIN and therefore the adequacy of secondary ablation is much harder to assess
- the successful treatment of one area of CIN does not preclude the future development of further areas of CIN or vaginal intraepithelial neoplasia (VAIN)
- where CIN is associated with foci of CGIN, careful attention will need to be paid to the CGIN component of the lesion.

The subsequent detection of additional foci of disease is therefore not necessarily indicative of treatment failure. CIN is identified, over a 10-year period, in up to 10% of women following treatment for CIN, this representing both persistent and recurrent disease.

8.3 Cervical glandular intraepithelial neoplasia

Unlike a diagnosis of primary CIN, a diagnosis of primary CGIN does not necessarily indicate that there is a single area of disease. In some cases, the disease will be multifocal.^{8,32,33} The persistence in the cervical smear of glandular atypia after treatment may alert the clinician to this possibility.

There are two important factors for future management:

- follow-up of treated endocervical lesions by repeat smear may be difficult if there is a lesion in the endocervical canal, and the use of an endocervical brush is recommended
- colposcopy is of limited help in these cases as there are no specific colposcopic features of CGIN and, indeed, the cervix may appear normal.

8.4 Microinvasive carcinoma

Ideally, the definition of microinvasive carcinoma should exclude all cases in which there is a significant risk of metastatic or recurrent disease. In our present state of knowledge, this is almost impossible. In the following comments on the risk of recurrent and residual disease it is assumed that the invasive focus or foci and the associated CIN have been completely removed.

8.4.1 *Microinvasive squamous cell carcinoma*

For the type of squamous lesions included in FIGO stage IA1, it is helpful to distinguish between those lesions previously termed 'early stromal invasion' and those which constitute a small, confluent invasive carcinoma. In respect of early stromal invasion, it is generally agreed that there is little or no risk of metastatic disease, though rare anecdotal cases have been described.^{34,35} Occasional examples of recurrent invasive disease of more advanced stage have been reported five or more years after the treatment of early stromal invasion.³⁴

A patient with a diagnosis of a FIGO stage IA1 lesion is not free from the risk of metastatic disease.^{36,37} It is difficult to determine from the published data what the precise risk of metastatic disease may be as people have used different criteria for the diagnosis of a microinvasive lesion. The risk is, however, believed to be very low.^{36,38} Progression to overt invasive carcinoma has been reported in 2.4% of cases³⁴ and invasive carcinoma reported in one patient who had been treated 12 years previously.³⁹

It is well recognised that lesions coming within FIGO stage IA2 will contain a small number of lesions which have metastasised, this risk being put at between 1 and 2%.^{36,39-44} A review of the literature suggests that a recurrence rate of 4.2% may be experienced for women who have been treated for FIGO stage IA2.⁴³

8.4.2 *Microinvasive adenocarcinoma*

There is little information in the literature on the outcome of the treatment of microinvasive adenocarcinoma.¹⁸ This stems from its relative rarity, the absence of agreed diagnostic criteria, and a reluctance to treat conservatively a lesion that is not fully understood.

APPENDIX 1: GENERAL ADVICE ON THE HANDLING OF BIOPSIES

A1.1 Punch biopsies and wedge biopsies

1. People may find it helpful to fix small punch biopsies in eosin-tinted formalin as this makes them easier to see and orientate.
2. The biopsy must be handled carefully to prevent trauma to, or loss of, the covering epithelium. It should be orientated carefully and the whole of the tissue processed and sectioned. As the appearance of the tissues, even in small biopsies, often shows considerable variation, several levels are required to ensure that small foci of disease are identified.

A1.2 Loop excisions and cone biopsies

1. Loop excisions are often received in more than one piece. This must be clearly indicated in the report. It may be helpful to store an image of the specimen that also indicates the system of sectioning (see below).
2. Loop and cone biopsies may be received opened or closed. The surgeon should be encouraged to submit the tissue closed as this reduces trauma to the epithelium and allows the pathologist accurately to identify the resection margins and assess the completeness of excision of any lesion.
3. The tissue must be examined in its entirety and cut so that the whole of the epithelium of the transformation zone can be examined, so that the resection margins are seen, and so that any invasive lesion can be measured.
4. There are two main methods of cutting cone or intact loop biopsies. The pathologist should be aware of the advantages and disadvantages of the two methods:¹⁹
 - the tissue may be cut in parallel slices. This is the method strongly recommended for specimens received intact. It may also be cut in a radial fashion, but there are disadvantages associated with this method¹⁹
 - when the cone or loop has been opened before receipt, it may have to be cut radially. The pathologist must bear in mind, however, that opening a cone or loop biopsy may cause damage to the epithelium.
5. The pieces of tissue obtained from the specimen should, ideally, each be placed in a separate cassette for processing.
6. Initially, a single level from each block may suffice. If there are difficulties in identifying the source of the abnormal cells seen in the cervical smear, deeper levels are mandatory. Multiple levels are also strongly recommended if there is extensive involvement of the surface epithelium and if there is deep involvement of endocervical crypts by expansile CIN, luminal necrosis and intraepithelial squamous maturation, as these features are associated with an increased risk of invasive disease (Figures 47 and 48).⁴⁵

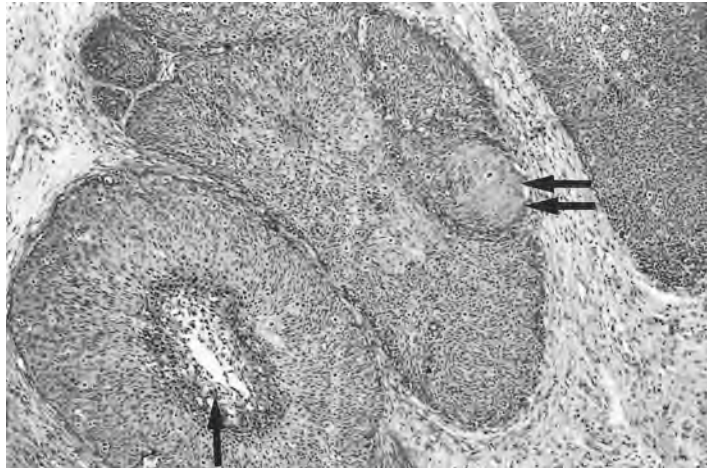


Figure 47 Features in CIN raising the suspicion of invasion. The crypts are lined by an epithelium with the features of CIN3 including intraepithelial pearls (arrows) and are distended by dyskeratotic cells (arrow).

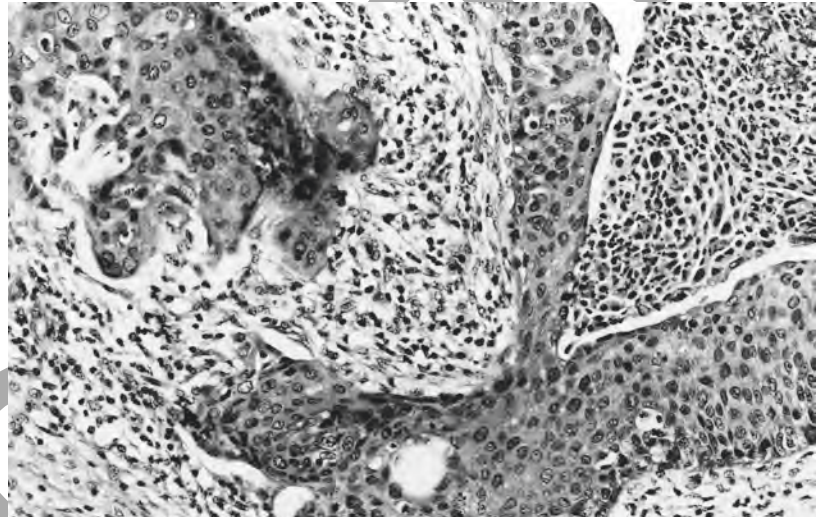


Figure 48 Microinvasive squamous cell carcinoma (to the upper left) arising from a crypt lined by an epithelium with features of CIN3. Note that the crypt contains desquamated dyskeratotic, dyskaryotic cells.

A1.3 Hysterectomy specimens

1. Cervical epithelial abnormalities will be detected in hysterectomy specimens in two different circumstances:
 - there may be a clinical indication for hysterectomy in a woman known to have had an abnormal cervical smear
 - a cervical epithelial abnormality may be detected unexpectedly on routine examination of the cervix. This possibility should always be borne in mind when choosing the method of uterine sampling.
2. In the first instance, it is recommended that the cervix is removed from the uterus prior to opening of the corpus so that it can be cut in parallel slices as described for a cone or loop biopsy (see 4 above).

3. In cases where the uterus has already been opened and sampled before the cervical lesion is detected and only two tissue blocks have been removed, one from the anterior and one from the posterior lip, the remaining pieces of tissue can be blocked as described in 4 above. Where sampling of the cervix has rendered such an approach impossible, the remaining tissue should be blocked so that the pathologist can identify the whole of the remaining lesion to ensure that the resection margins are free from disease and to enable any invasive lesion to be measured.

Withdrawn

APPENDIX 2: REGISTRATION OF CERVICAL CANCERS

A2.1 Requirements for transfer of data

The histopathology report should be transferred in its entirety to the cancer registry. The nomenclature used in this document is preferred, and it is recommended that cancer registries should consider moving towards registering CIN1, CIN2 and CGIN in addition to the data required for cancer registration purposes in order to assist the monitoring of the screening programme. The NHSCSP wishes, in particular, to see the following aspects of the data recorded:

- squamous and glandular intraepithelial neoplasia accurately recorded
- the highest grade of CIN or CGIN present even if this is only CIN1 or low-grade CGIN; where both CIN and CGIN are present, both should be recorded
- the histological type of all carcinomas recorded to provide accurate data and to allow detection of changes in incidence
- data relating to gynaecological tumours should be registered using the FIGO staging system.

A2.2 Coding

All cancer registries are now using ICD-10 site coding and ICD-0 morphology coding.⁴⁷ ICD-0 morphology codes are also used in the SNOMED coding system used by many pathologists. This Appendix is intended to assist pathologists in ensuring that diagnoses of CIN3 and invasive cervical cancer are correctly recorded at the cancer registry using this coding system. Cervical malignancies, whether *in situ* or invasive, should not be notified on cytology alone for incidence purposes.

A2.3 Site

Each case will be assigned a site code indicating the location of the lesion. These are shown in Table A1.

Table A1

	Malignant neoplasm of cervix uteri	Carcinoma <i>in situ</i> of cervix uteri (includes CIN3)
	C53	D06
Endocervix	C53.0	D06.0
Exocervix	C53.1	D06.1
Other parts of cervix uteri	C53.8	D06.7
Overlapping lesion	C53.8	D06.7
Cervix uteri, unspecified	C53.9	D06.9

A2.4 Morphology (including keratinisation)

Each case registered will also be assigned a morphology code indicating tumour type. A single tumour with different histological types (e.g. CGIN with a squamous component) will be assigned the highest morphology code applicable. For a multiple registration to be made, there must be identifiably separate tumours of different morphology. The main codes

in use are given in Table A2.

Table A2

	Invasive	<i>In situ</i>
Squamous cell	See Table A3	8077/2 (CIN3)
Adenocarcinoma	8140/3	8140/2 (CGIN)
Adenosquamous	8560/3	8560/2

A2.5 Grading

Grading must be specified as grades 1, 2, 3 or as well/good, moderate, poor respectively. Keratinisation alone will not be accepted as a grade for cancer registration purposes. (See paragraph 5.2 of the report for further advice and equivalency.) For invasive squamous cell carcinomas, both keratinisation and grading information should be supplied as in Table A3.

Table A3

Type	Morphology code	Grade
Invasive large cell keratinising	8071/3	1/well
Invasive large cell focally keratinising	8071/3	2/moderate
Invasive large cell non-keratinising	8072/3	2/moderate
Invasive small cell non-keratinising	8073/3	3/poor

A2.6 Staging

FIGO staging should be used.¹⁷ This will require liaison between gynaecologists and pathologists. The responsibility for recording stage and notification of the cancer should be determined at the intention-to-treat stage. TNM staging can be mapped from FIGO staging if required. If TNM staging only is available, depth must be recorded.

APPENDIX 3: ELECTRONIC DATA TRANSFER OF HISTOPATHOLOGY RESULTS

The systems of paper transfer between agencies in the NHSCSP are being replaced by electronic links between computers and, increasingly, electronic data interchange (EDI). EDI is the process, based upon agreed standards, which enables computers in different organisations to send business or information transactions directly from one to the other. This reduces the number of times that data are manually re-entered into computers and the number of consequent transcription errors. EDI in the screening programme has, until recently, focused on information relating to cervical smears and their management, and upon the information flows between laboratories and health authorities. This is now changing as a result of the information strategy for the NHS, increasing demand by general practitioners for 'computer links' to laboratories, and the establishment of electronic data flows between health authorities and general practice. The broadened scope of the screening programme includes diagnostic biopsy and local excision of abnormalities detected by screening cytology and there is, consequently, a need to include information from histological reports in the health authority record and for this to be provided by laboratories. A woman is no longer 'suspended' from the screening programme when she is referred to a gynaecologist for investigation and treatment.

The health authority will, when the development of a histopathology data set and software to manage it is complete, be able to hold a full screening history rather than just a smear history. This will mean that, when a woman moves to another area or is referred to another hospital, a complete screening record will be available from the health authority with which she is or was most recently registered. A full record of previous events will be available to a laboratory reporting a biopsy or excision specimen, and a laboratory reporting a smear will be able to obtain data on a subsequent biopsy from this single source for correlation and positive predictive value calculation.

The information needs of the screening programme are consistent and the number of data items is finite. It is, therefore, possible to define standard messages for EDI which meet NHS, national and European standards, which are explicit and which concentrate on data needed and not already held by the recipient. A set of standard messages for cervical screening has been developed, as part of the NHS clinical messages development programme. The working group was made up of laboratory staff including representatives of the Royal College of Pathologists and the British Society for Clinical Cytology, general practitioners, health authority staff and representatives of FHS, the supplier of software for the health authority computer system. These messages include code sets, which identify broad categories of biopsies or resection samples and of histological results (Tables A4 and A5). The definitions relating to these codes are not intended to identify every individual type of sample and

Histopathology Reporting in Cervical Screening

specifically not intended to represent all possible diagnoses that may be used in a report to the clinician responsible for a given patient. This situation is analogous to that which exists for cervical smear results.

The relation among these diagnostic synopsis codes and terms and codes used in a clinical report can be mapped as illustrated in Figure A1. This is not an exhaustive list of clinical diagnoses but reflects terms used in

Table A4 Biopsy sample type codes

Description	Code
Punch/wedge biopsy (a biopsy taken for diagnostic purposes and not intended for ablation of all abnormal epithelium)	CP
Cone biopsy (a biopsy taken by knife, diathermy or any other means and intended for ablation of all abnormal epithelium, with or without total removal of the transformation zone)	CC
Endocervical biopsy (diagnostic biopsy of the endocervical canal)	EC
Endometrial biopsy (all endometrial samples other than hysterectomy)	EB
Hysterectomy – partial (a hysterectomy where there is evidence that the transformation zone has <i>not</i> been completely removed)	HP
Hysterectomy – total (a hysterectomy where <i>the whole</i> of the transformation zone has apparently been removed)	HT

Table A5 Biopsy result synopsis codes

Description	Code
Inadequate/non-representative biopsy	XX
Normal	NN
Inflammatory changes	IC
Other benign and non-neoplastic abnormalities not listed	BB
Virus-associated changes	CV
Epithelial changes of uncertain significance	CB
CIN1	C1
CIN2	C2
CIN3	C3
Ungraded CIN	CU
Microinvasive squamous cell carcinoma of the cervix (FIGO stage 1A)	CM
Squamous cell carcinoma of the cervix (FIGO stage more than 1A)	CS
Adenosquamous carcinoma of the cervix	AS
CGIN (all grades of cervical glandular intraepithelial neoplasia and adenocarcinoma <i>in situ</i> (ACIS))	CG
Adenocarcinoma of the cervix	CA
Endometrial hyperplasia without atypia	EH
Atypical endometrial hyperplasia	EA
Endometrial carcinoma	EC
Other malignant abnormalities not listed	MB

Histopathology Reporting in Cervical Screening

this document and in common usage. Mapping will be the basis of a translation table, which should be included in histopathology laboratory computer system applications for any laboratory intending to establish EDI links with the local health authority, and which can also be used with manual, paper-based systems. The number of diagnostic variations used by the laboratory is a matter for local decision, subject to the principles and recommendations elsewhere in this document, but the code set held at the health authority and into which the laboratory diagnoses are collapsed is limited to that given here.

Figure A1 Mapping of clinical diagnoses to biopsy synopsis codes

Diagnoses	Code
Inadequate sample Non-representative sample	XX
Normal biopsy Normal cervical tissues	NN
Chronic cervicitis Active chronic cervicitis Lymphocytic cervicitis Inflammatory changes	IC
Basal cell hyperplasia Metaplasias Atrophic/post-menopausal changes Low-oestrogen status Progestagen-associated changes Microglandular hyperplasia Arias Stella changes Endocervical polyps Endometriosis	BB
HPV-associated changes HPV-like features Papillomavirus changes Virus-associated changes Koilocytosis Koilocytosis-associated changes Condyloma acuminatum	CV
Epithelial changes of uncertain significance Basal cell atypia of uncertain significance (BAUS)	CB
CIN1	C1
CIN2	C2
CIN3	C3

Histopathology Reporting in Cervical Screening

Ungraded CIN		CU
CGIN high grade		
CGIN low grade		
Adenocarcinoma <i>in situ</i> (ACIS)		CG
Early stromal invasion (ESI)		
Microinvasive squamous cell carcinoma		
Microinvasive small cell squamous cell carcinoma		
Microinvasive keratinising squamous cell carcinoma		
Microinvasive non-keratinising squamous carcinoma		
Any of the above tumours FIGO stage IA		
Any of the above tumours FIGO stage IA/IA2		CM
Invasive squamous cell carcinoma		
Invasive small cell squamous carcinoma		
Invasive keratinising squamous cell carcinoma		
Invasive non-keratinising squamous cell carcinoma		
Any of the above tumours FIGO stage IB or more		CS
Adenosquamous carcinoma any size		AS
Invasive adenocarcinoma any type		
Adenocarcinoma any type equivalent in size to FIGO stage IA		CA
Small cell neuroendocrine carcinoma		
Small cell undifferentiated carcinoma		
Verrucous carcinoma		
Glassy cell carcinoma		
Lymphoepithelioma-like carcinoma		
Adenoid basal carcinoma		
Adenoid cystic carcinoma		
Mixed epithelial stromal tumours		
Stromal tumours		
Smooth muscle tumours		
Other non-gynaecological tumours		MB
Endometrial hyperplasia without atypia		EH
Atypical endometrial hyperplasia		EA
Endometrial carcinoma any type		EC

REFERENCES

1. Anderson M C et al. Current views on cervical intraepithelial neoplasia. *Journal of Clinical Pathology*, 1991, 44: 969–978.
2. Solomon D. The 1988 Bethesda system for reporting cervical/vaginal cytological diagnoses. *Acta Cytologica*, 1989, 33: 567–574.
3. Winkler B et al. Koilocytotic lesions of the cervix: the relationship of mitotic abnormalities to the presence of papillomavirus antigens and nuclear DNA content. *Cancer*, 1984, 53: 1081–1087.
4. Jenkins D et al. Histological and immunocytochemical study of cervical intraepithelial neoplasia associated with HPV 6 and HPV 16 infections. *Journal of Clinical Pathology*, 1986, 39: 1177–1180.
5. Blackett A D, Conyers M G, Sharp F. The incidence of HPV and EBV DNA in normal, koilocytic, and dysplastic cervical tissue. *British Journal of Obstetrics and Gynaecology*, 1994, 101: 814.
6. Buckley et al. Borderline nuclear changes in cervical smears: guidelines in their recognition and management. A report of the Joint National Coordinating Network, British Society of Clinical Cytology, and the Royal College of Pathologists Working Party. *Journal of Clinical Pathology*, 1994, 47: 481–492.
7. Young R H, Clement P B. Tumorlike lesions of the uterine cervix. In: Clement P B, Young R H (eds). *Tumors and Tumorlike Lesions of the Uterine Corpus and Cervix*. New York, Churchill Livingstone, 1993, 1–50.
8. Östör A G et al. Adenocarcinoma in situ of the cervix. *International Journal of Gynecological Pathology*, 1984, 3: 179–190.
9. Brown J L R, Wells M. Cervical glandular atypia associated with squamous intraepithelial neoplasia: a premalignant lesion? *Journal of Clinical Pathology*, 1986, 39: 22–28.
10. Gloor E, Hurliman J. Cervical intraepithelial glandular neoplasia (adenocarcinoma in-situ and glandular dysplasia). *Cancer*, 1986, 58: 1272–1280.
11. Widrich T et al. Adenocarcinoma in situ of the uterine cervix: management and outcome. *Gynecologic Oncology*, 1996, 61: 304–308.
12. Ismail S M. Cone biopsy causes cervical endometriosis and tuboendometrioid metaplasia. *Histopathology*, 1991, 18: 107–114.
13. Al-Nafussi A I, Rahilly M. The prevalence of tubo-endometrioid metaplasia and adenomatoid proliferation. *Histopathology*, 1993, 22: 177–179.
14. Ferry J A, Scully R E. Mesonephric remnants, hyperplasia, and neoplasia in the uterine cervix: a study of 49 cases. *American Journal of Surgical Pathology*, 1990, 14: 1100–1111.
15. Valente P T, Susin M. Cervical adenocarcinoma arising in florid mesonephric hyperplasia: report of a case with immunohistochemical studies. *Gynecologic Oncology*, 1987, 27: 58–68.
16. Lowe D G, Buckley C H, Fox H. Advances in gynaecological pathology. In: Anthony P P, MacSween R N M, Lowe D G (eds). *Recent Advances in Histopathology*. Edinburgh, Churchill Livingstone, 1997, 113–137.
17. Shepherd J H. Staging announcement. FIGO staging of gynecologic cancers; cervical and vulva. *International Journal of Gynecological Cancer*, 1995, 5: 319. (Published erratum appears in *International Journal of Gynecological Cancer*, 1995, 5: 465.)
18. Östör A G, Rome R, Quinn M. Microinvasive adenocarcinoma of the cervix: a clinicopathologic study of 77 women. *Obstetrics and Gynecology*, 1997, 89: 88–93.
19. Anderson M C. Premalignant and malignant squamous lesions of the cervix.

- In: Fox H (ed.). *Haines and Taylor: Obstetrical and Gynaecological Pathology*, 2nd edn. Edinburgh, Churchill Livingstone, 1995, 273–322.
20. Buckley C H. Tumors of the cervix uteri. In: Fletcher C D M (ed.). *Diagnostic Histopathology of Tumors*. Edinburgh, Churchill Livingstone, 1995, 478–494.
 21. Griffin N R, Wells M. Premalignant and malignant glandular lesions of the cervix. In: Fox H (ed.). *Haines and Taylor: Obstetrical and Gynaecological Pathology*, 2nd edn. Edinburgh, Churchill Livingstone, 1995, 323–343.
 22. Shepherd J H. Revised FIGO staging for gynaecological cancer. *British Journal of Obstetrics and Gynaecology*, 1989, 96: 887.
 23. American College of Obstetricians and Gynecologists. Carcinoma of the endometrium. ACOG Technical Bulletin Number 162, December 1991. *International Journal of Gynaecology and Obstetrics*, 1993, 40: 255–261.
 24. Scurry J, Patel K, Wells M. Gross examination of uterine specimens. *Journal of Clinical Pathology*, 1993, 46: 388–393.
 25. Pritchard J. *Quality Assurance Guidelines for the Cervical Screening Programme*. Sheffield, NHS Cervical Screening Programme, 1997 (NHSCSP Publication No 3).
 26. Mitchell H, Medley G. Differences between Papanicolaou smears with correct and incorrect diagnoses. *Cytopathology*, 1995, 6: 368–375.
 27. Stanbridge C M et al. A cervical smear review in women developing cervical carcinoma with particular reference to age, false negative cytology and the histologic type of the carcinoma. *International Journal of Gynecological Cancer*, 1992, 2: 92–100.
 28. Smith PA, Turnbull LS. Small cell and 'pale' dyskaryosis. *Cytopathology*, 1997, 8: 3–8.
 29. Gray J A M, Farmery E. *Assuring the Quality and Measuring the Effectiveness of the Cervical Screening Programme*. Oxford, National Coordinating Network, 1994.
 30. Herbert A et al. *Achievable Standards, Benchmarks for Reporting and Criteria for Evaluating Cervical Cytopathology*. Sheffield, NHS Cervical Screening Programme, 1995 (NHSCSP Publication No 1).
 31. Patnick J, Winder R (eds). *Cervical Screening: a Practical Guide for Purchasers*. Sheffield, NHS Cervical Screening Programme, 1997 (NHSCSP Publication No 3).
 32. Bertrand M, Lickrish G M, Colgan T J. The anatomic distribution of cervical adenocarcinoma in situ: implications for treatment. *American Journal of Obstetrics and Gynecology*, 1987, 157: 21–25.
 33. Wolf J K et al. Adenocarcinoma in situ of the cervix: significance of cone biopsy margins. *Obstetrics and Gynecology*, 1996, 88: 82–86.
 34. Burghardt E et al. Microinvasive carcinoma of the uterine cervix (International Federation of Gynecology and Obstetrics Stage IA). *Cancer*, 1991, 67: 1037–1045.
 35. Collins H S et al. Widespread lymph node metastases in a patient with microinvasive cervical carcinoma. *Gynecologic Oncology*, 1989, 34: 219–221.
 36. Tsukamoto N et al. The problem of Stage Ia (FIGO, 1985) carcinoma of the uterine cervix. *Gynecologic Oncology*, 1989, 34: 1–6.
 37. Girard F et al. Small FIGO stage Ib cervical cancer. *Gynecologic Oncology*, 1994, 55: 427–432.
 38. van Nagell J R Jr et al. Microinvasive carcinoma of the cervix. *American Journal of Obstetrics and Gynecology*, 1983, 145: 981–991.
 39. Copeland L J et al. Superficially invasive squamous cell carcinoma of the cervix. *Gynecologic Oncology*, 1992, 45: 307–312.
 40. Averette H E. Diagnosis and management of microinvasive (stage IA) carcinoma of the uterine cervix. *Cancer*, 1976, 38: 414–425.

41. Ito T et al. Colposcopy in dysplasia, carcinoma in situ and microinvasive cancer of the cervix – systematic diagnosis. *Nippon Sanka Fujinka Gakkai Zasshi*, 1986, 38: 168–176.
42. Monaghan J M. Management decision using clinical and operative staging in cervical cancer. *Clinics in Obstetrics and Gynaecology*, 1988, 2: 737–746.
43. Sevin B U et al. Microinvasive carcinoma of the cervix. *Cancer*, 1992, 70: 2121–2128.
44. Ueki M et al. Conservative therapy for microinvasive carcinoma of the uterine cervix. *Gynaecologic Oncology*, 1994, 53: 109–113.
45. Al-Nafussi A I, Hughes D E. Histological features of CIN3 and their value in predicting invasive microinvasive squamous carcinoma. *Journal of Clinical Pathology*, 1994, 47: 799–804.
46. Clement P B. Miscellaneous primary tumours and metastatic tumours of the uterine cervix. In: Fox H (ed.). *Haines and Taylor: Obstetrical and Gynaecological Pathology*, 2nd edn. Edinburgh, Churchill Livingstone, 1995, 345–364.
47. *International Statistical Classification of Diseases and Related Health Problems*. Tenth revision. WHO, Geneva 1994.